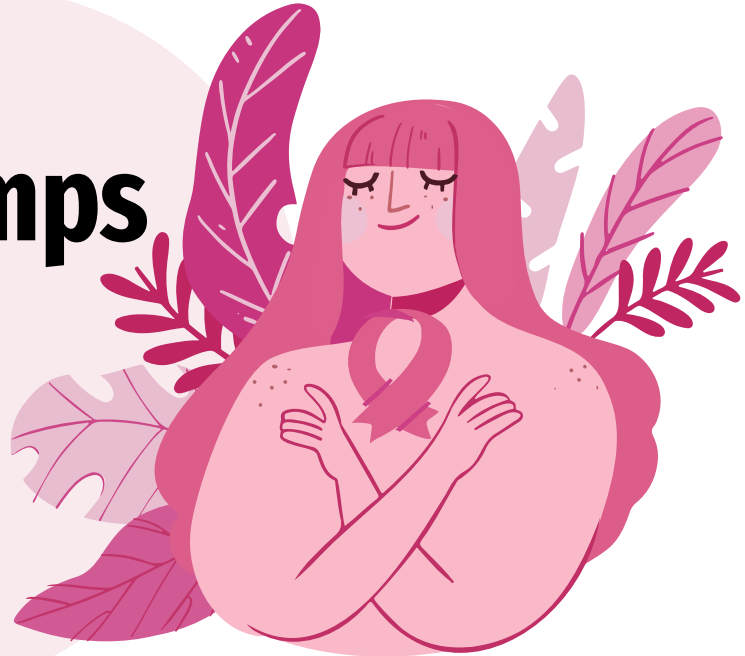

Approach to Breast Lumps



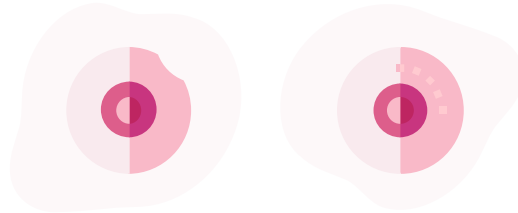
Credit to:

- Dr. Noranissa
- Dr. Rubenraaj
- Dr. Sufiana
- Dr. Foo Ying

CONTENTS

01

ANATOMY OF BREAST

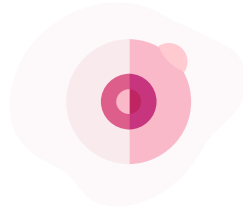


CANCER

04

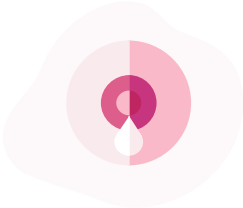02

TRIPLE ASSESSMENT



03

BENIGN BREAST
DISEASES




ANATOMY OF BREAST

1. Introduction

2. External Features

3. Internal Features

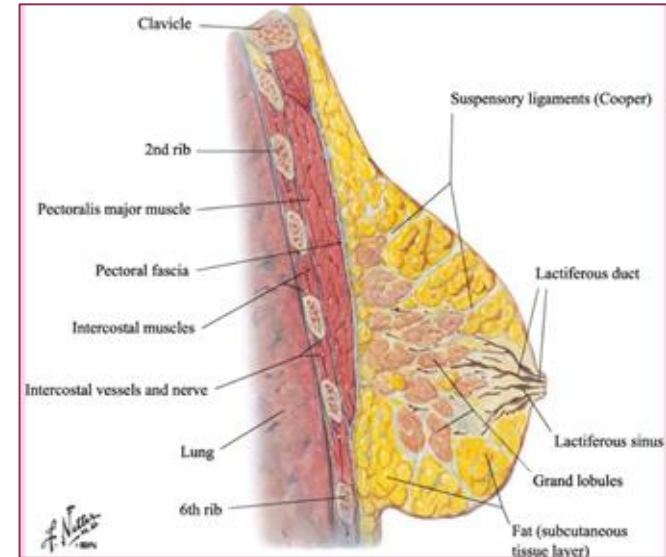
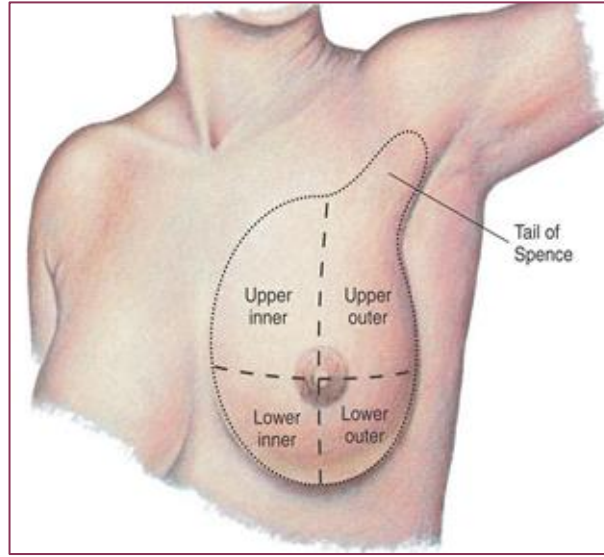
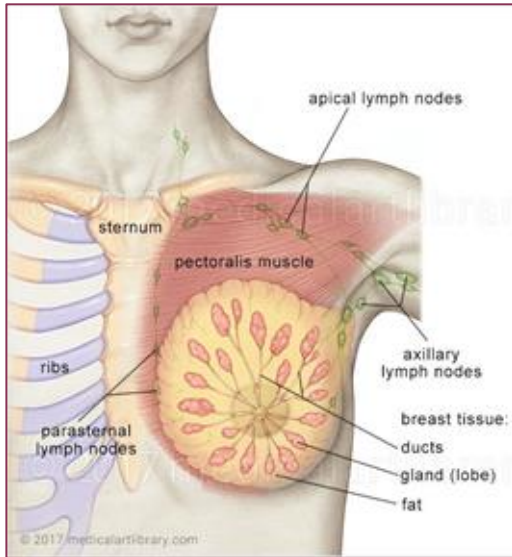


4. Blood Supply

5. Lymphatic Drainage

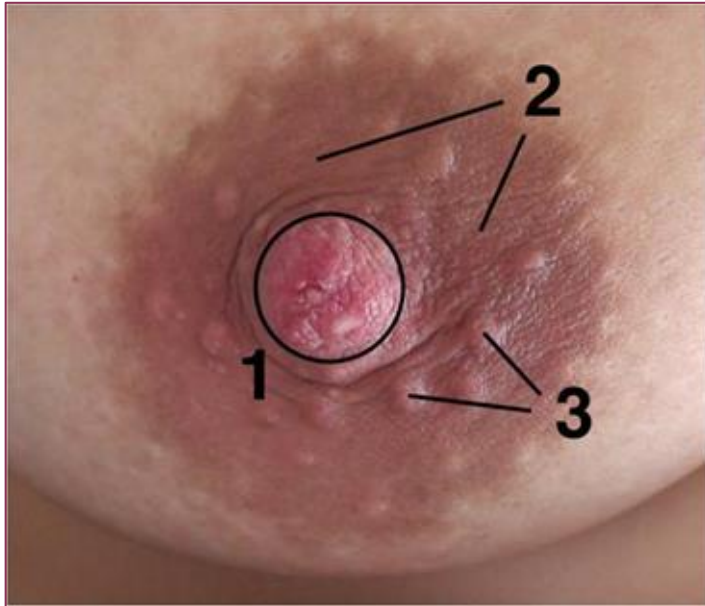
6. Innervations

Introduction



- Glandular and supporting fibrous tissue embedded within fatty matrix with blood vessels, lymphatics and nerves
- **Lateral border of sternum to midaxillary line**
- **2nd to 6th ribs**
- **Axillary tail**
- Lies in the superficial fascia of pectoral region

External Features



1. Nipple

- Cylindrical prominence at the centre of areola
- Lactiferous duct opening

1. Areola

- Circular pigmented area
- Contains sebaceous glands
- No fat tissue, no hair follicle

1. Areolar gland / Montgomery's gland

- Sebaceous glands forming round projections from the surface of areola
- Secrete oily sebum to lubricate areola and nipple

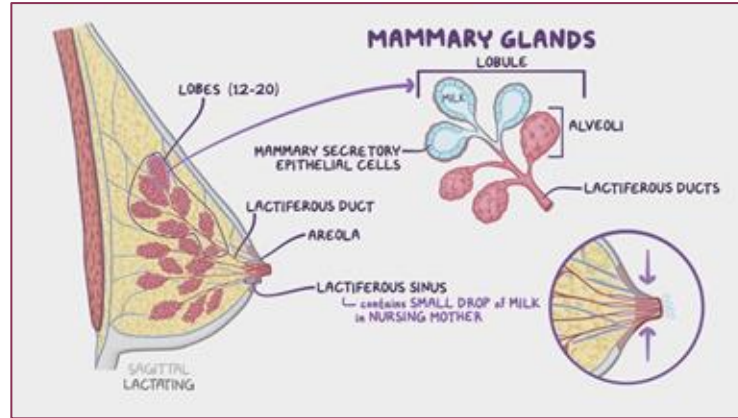
Internal Features

Suspensory ligaments of Cooper

- Condensation of fibrous connective tissue
- Mammary gland attach firmly to dermis of overlying skin by the ligament
- Support lobes and lobules

Lobes & Lobules

- Embedded in connective tissue & fat
- Lobe composed of lobules
- Lobules composed of alveoli
- Secretes milk



Lactiferous sinus (ampulla)

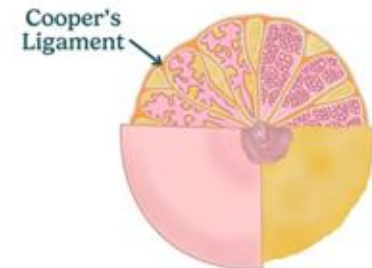
- Dilatation of lactiferous duct
- Store droplet of milk
- Allow expression of milk by compression of areolar

Lactiferous duct

- Excretory duct that drains each lobes
- Opening on surface of nipple

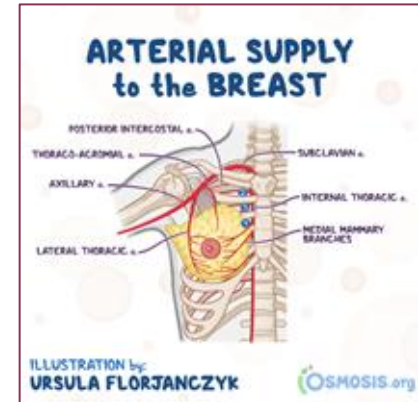
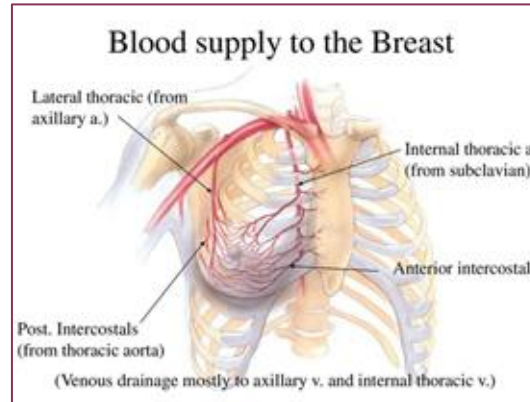
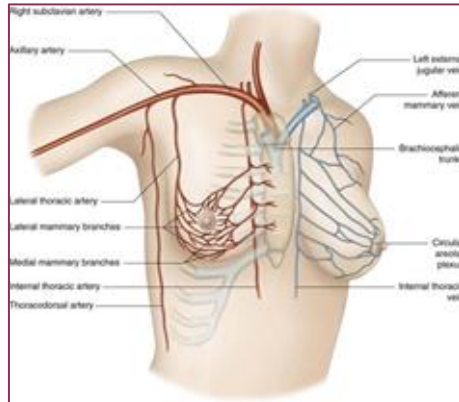
Retromammary space (bursa)

- Potential space between breast and pectoral fascia
- Contains fat and lymphatic tissue
- Allows breast movement and lobules



Arterial supply

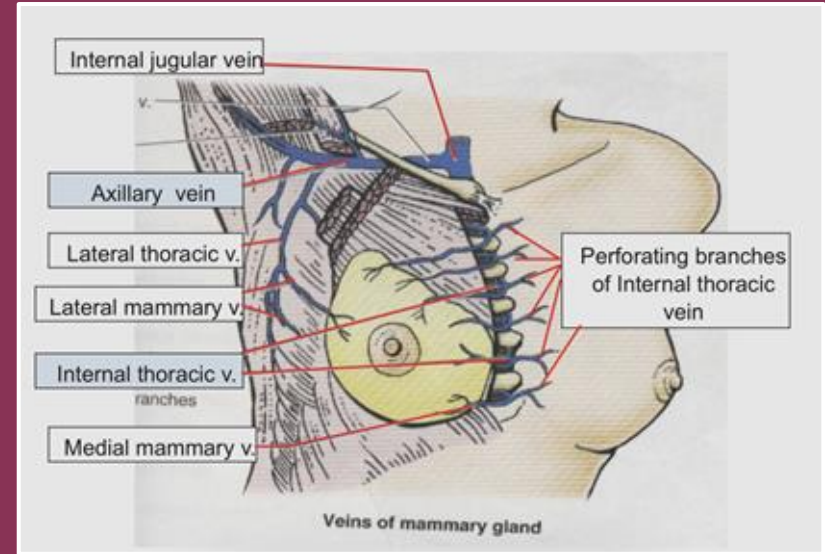
Source	Branches
Internal Thoracic Artery	<ul style="list-style-type: none"> ● Medial mammary branches of perforating branches ● Anterior intercostal branches
Thoracic Aorta	<ul style="list-style-type: none"> ● Posterior intercostal artery in the 2nd, 3rd & 4th intercostal space
Axillary Artery (2nd part)	<ul style="list-style-type: none"> ● Thoracoacromial artery ● Lateral thoracic artery



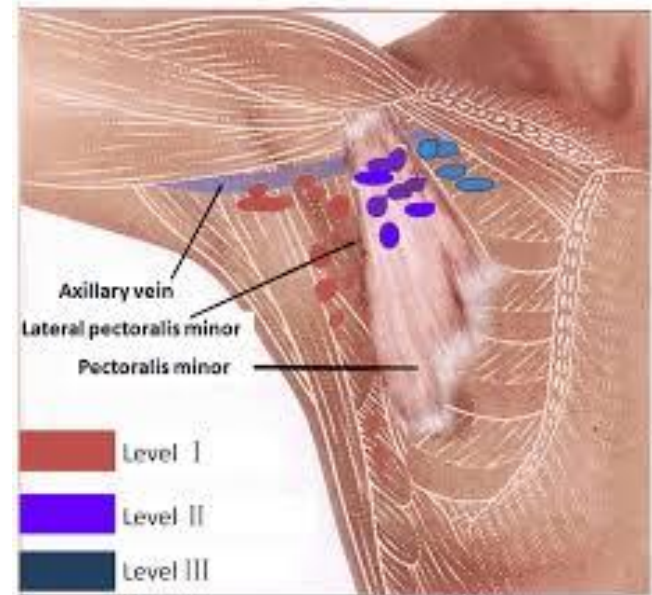
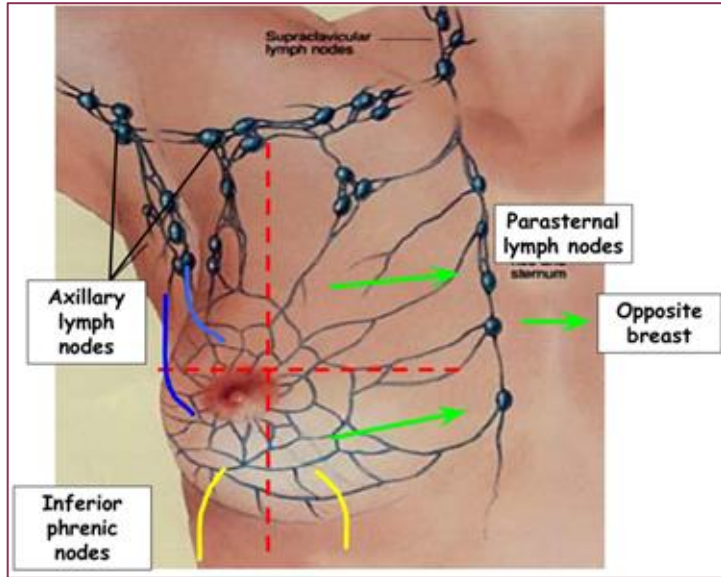
Venous drainage

Drained by superficial and deep veins that accompany the arteries:

- Axillary vein (main)
- Internal thoracic vein
- Posterior Intercostal veins



Lymphatic drainage



Triple Assessment

The gold standard for evaluating any palpable breast lump

1



Clinical

History + Examination

- Risk factors
- Lump characteristics
- Nipple, skin, nodes

2



Imaging

USG ± Mammogram

- USG: < 35 yrs
- Mammo + USG: ≥ 35 yrs
- MRI in selected cases

3



Pathology

Core needle biopsy

- CNB preferred over FNAC
- Cytology if cystic
- Image-guided if impalpable

Concordance of all 3 components → high diagnostic accuracy (> 99%)

History Taking

Targeted questions that actually change management

The lump itself

Onset When first noticed? Self vs incidental on imaging?

Duration & growth Stable, slowly growing, or rapidly enlarging?

Pain Cyclical (hormonal) vs constant. Cancer often painless.

Changes with cycle Fluctuates with menses → fibrocystic

Nipple changes Discharge (bloody?), retraction, eczema, ulceration

Skin changes Dimpling, peau d'orange, ulcer, redness, warmth

Trauma / surgery Recent trauma, biopsy, surgery → fat necrosis

Risk factors & background



Age Strongest single risk factor



Family history 1st-degree relative with breast/ovarian Ca; age at dx



Reproductive Menarche, menopause, parity, age at first child, breastfeeding



Hormonal OCP, HRT, IVF



Previous breast disease Atypical hyperplasia, LCIS, prior cancer



Lifestyle Obesity, alcohol, smoking, physical activity



Systemic Weight loss, bone pain, SOB, headache → mets screen

Clinical Examination

Position, expose properly, examine systematically



Position & expose

Sit then supine, both arms by side then raised. Adequate exposure & chaperone.



Inspect

Symmetry, skin (dimpling, peau d'orange, ulcer), nipple (retraction, discharge, eczema).



Palpate breast

Systematic — all 4 quadrants + axillary tail. Use flat of fingers. Examine normal side first.



Lymph nodes

Axillary (5 groups), supraclavicular, infraclavicular, cervical.

If a lump is found — document these characteristics

Site

Clock position + cm from nipple

Size

Measure in cm (use tape if needed)

Shape

Round, oval, irregular

Surface

Smooth, lobulated, irregular

Consistency

Soft, firm, hard, rubbery

Mobility

Mobile, tethered, fixed to skin/muscle

Tenderness

Painful or not

Skin/nipple

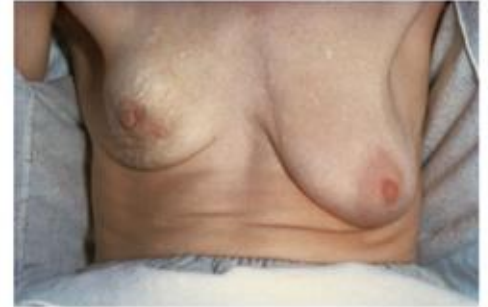Changes overlying the lump

Introduction

- Wash hand
- Self introduction
- Confirm patient's identity
- Briefly explain regarding the procedure
- Gain consent
- Privacy: close curtain and introduce chaperone
- Position: sitting upright at side of bed / prop up 45 degree
- Exposure: chest fully exposed down to umbilicus
- Ask if any pain before start physical

Inspection

1. **Scars** (may indicate previous breast surgery such as lumpectomy or mastectomy)
2. **Asymmetry** (it is common, so it is important to ask whether the asymmetry is new)
3. **Nipple abnormalities**
 - Nipple inversion: Possible pathological causes of nipple inversion include breast cancer, breast abscess, mammary duct ectasia and mastitis.
 - Nipple discharge:
 - Bilateral, multiductal, non-bloody discharge is usually benign and has an endocrine etiology.
 - Spontaneous, unilateral discharge requires diagnostic testing; this type of discharge may be cancer, particularly if it is bloody.
1. **Masses** (note any visible lumps that will require further assessment)
2. **Ulcers**
3. **Visible veins** (which, if unilateral, may suggest cancer)



Carcinoma of the right breast, showing elevation of the breast, dimpling of the skin and retraction of the nipple

FIGURE 41.2

Inspection

7. Skin changes

- Scaling
 - Scaling of the nipple and/or areola associated with erythema and pruritus are typical features of Paget's disease of the breast.
- Erythema
 - Can be mastitis (the area will be hot and tender)
 - A persistent erythematous plaque in the nipple area may be contact dermatitis or skin irritation, but if asymmetrical or it has not responded to treatment, this may be Paget's disease of the breast.
- Puckering/dimpling
 - Typically associated with invasion of the suspensory ligaments of the breast by an underlying malignancy that results in ligamentous contraction which draws the skin inwards.
- Peau d'orange
 - Occurs due to cutaneous lymphatic oedema.
 - The dimples represent tethering of the swollen skin to hair follicles and sweat glands.

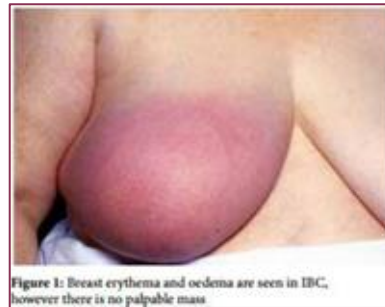
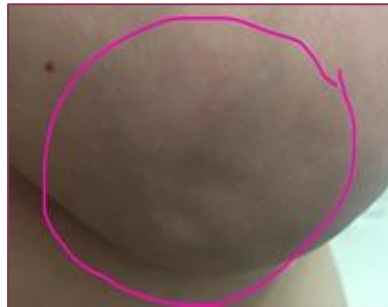
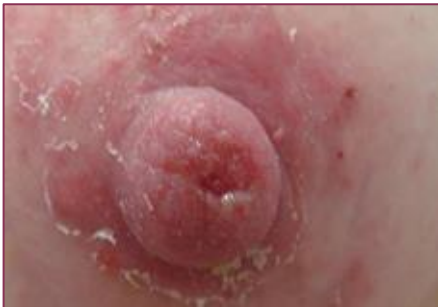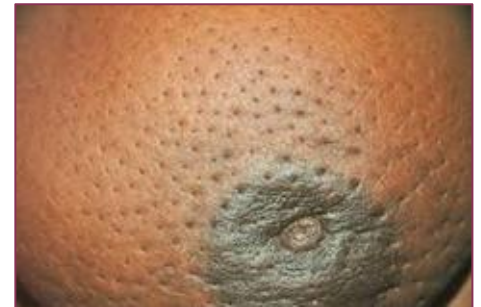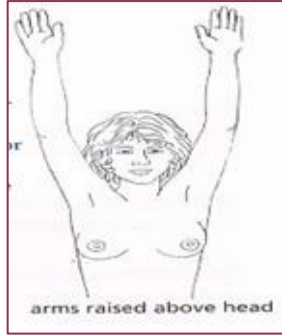Figure 1: Breast erythema and oedema are seen in IBC, however there is no palpable mass

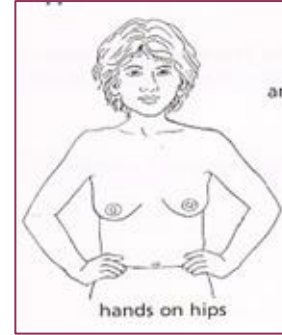


Inspection (Proceed with manouvre)



Ask the patient to raise the arms above the head and then lower them slowly.

- Look for tethering of the nipples or skin, a shift in the relative position of the nipples or a fixed mass distorting the breast.
- Note whether there are any obvious visible masses in the axillae.

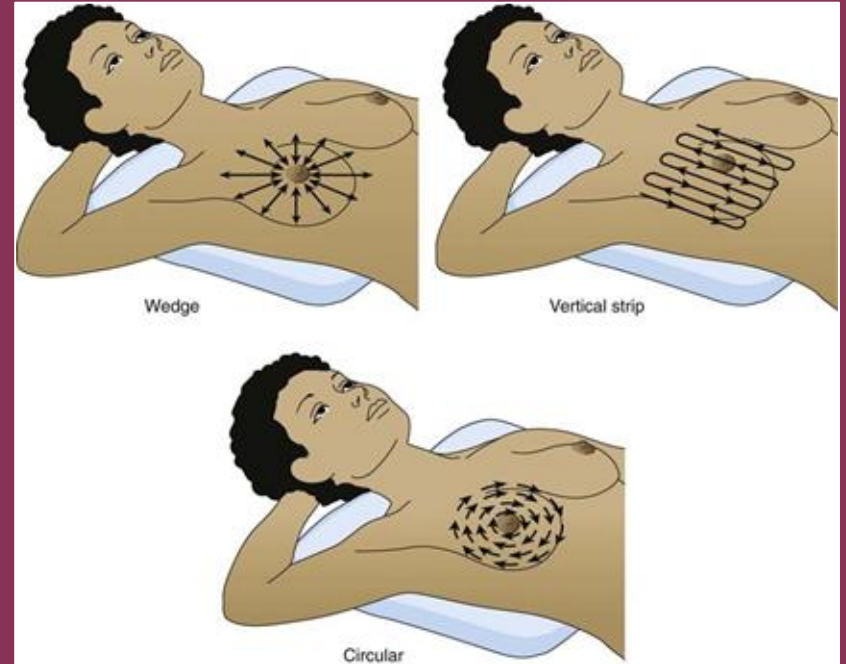


Pectoral contraction manoeuvre: Ask the patient to rest the hands on the hips and the press the hands against the hips

- If a mass is visible, observe if it moves when the pectoralis muscle contracts which suggests tethering to the underlying tissue (e.g. invasive breast malignancy).
- Helps to accentuate areas of dimpling or fixation

Palpation of the breast

1. Ask the patient to lie down on the bed at 45° while placing the hand behind the head
2. Place a towel beneath the patient's scapula
3. Ask the patient for any pain prior to the palpation
- 4. Palpate the unaffected breast first**
5. Gently use the pulps of the middle three fingers for palpation
6. The total examination should involve a area that are bordered by the clavicle, the sternum, the inframammary fold, the midaxillary line and the axillary tail
7. There is no single correct way to palpate the breast, as long as all sections are palpated



Palpation of the nipples

- Palpate behind the nipple for any lumps
- Inverted nipple - may everted by asking the patient to do it or by gentle squeezing the areolar edge
- Ask patient to show the discharge by demonstrating it herself
- We can also demonstrate it by gently pressing the areola to express the fluid
- Characterise the discharge: colour, consistency, volume

****BE CAREFUL NOT TO CAUSE ANY DISCOMFORT OR PAIN TO THE PATIENT**

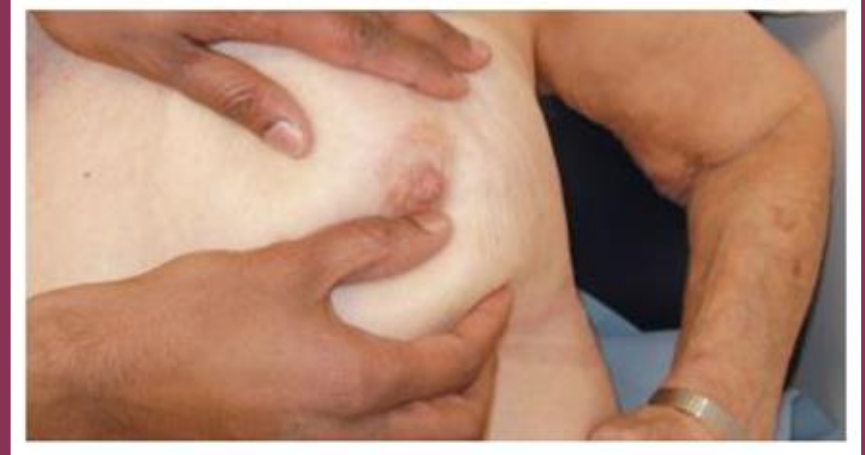TOP TIP

- ✓ The seven 'D's of nipple signs
- ✓ When inspecting the nipple, or taking a history of nipple symptoms, look for:
 - Discolouration
 - Discharge
 - Depression (often referred to as inversion)
 - Deviation
 - Displacement
 - Destruction
 - (Duplication – unlikely in the exam).

Fixation test

(Assess the mobility of mass)

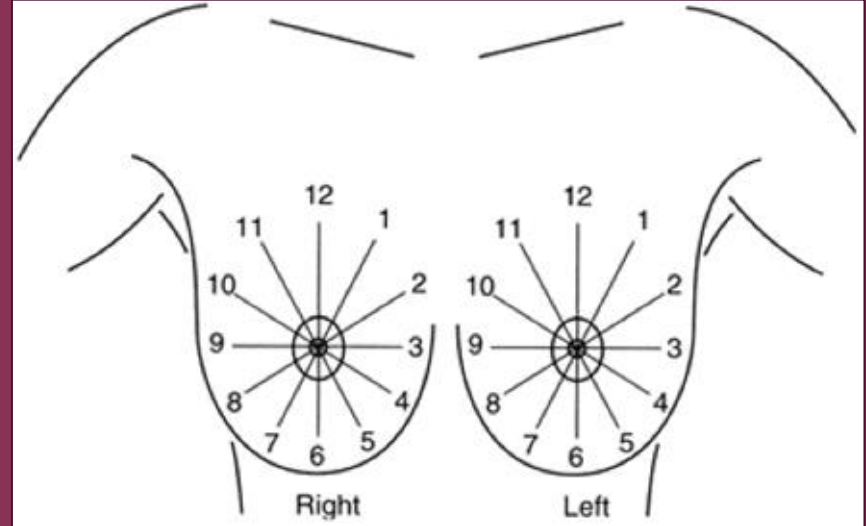
1. Fixity to the skin
 - The skin overlying the lump was gently pinched and moved with the fingers
1. Fixity to the muscle / chest wall
 - Request the patient to place her hands on her hips to contract the pectoralis muscle
 - Move the lump in the direction of the fibres first (transversely) and then move at the right angles (vertically)



Evaluation of breast lumps

1. **Site** (position): name the quadrant the lump is located within
2. **Size**: measure the lump approximately
3. **Surface**: smooth/irregular/nodular
4. **Edge**: well/poorly defined
5. **Consistency**: soft/firm/hard
6. **Tenderness**
7. **Fluctuation**

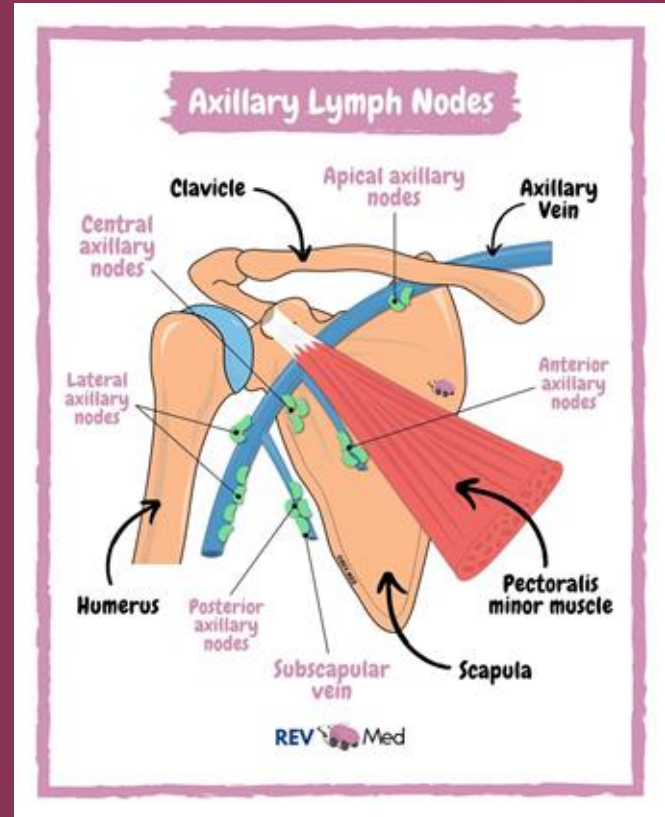
**Fixation: to skin or the underlying chest wall



Palpation of the Lymph Nodes

Examine supraclavicular and axillary region for lymphadenopathy:

1. Patient sit facing the examiner
2. Support patient's forearm with examiner's own forearm to ensure pectoralis muscle was relaxed
3. Palpate the apical, central, anterior and lateral axillary nodes, posterior axillary nodes and supraclavicular nodes



Imaging Modalities

Pick the right test for the right patient

Age-based first-line imaging

< 35 years

Ultrasound first

Dense glandular tissue → mammogram less useful. No radiation.
Distinguishes solid from cystic.

≥ 35 years

Mammogram + Ultrasound

Bilateral mammogram (CC + MLO views) + targeted USG. Detects microcalcifications.

MRI breast — selected cases only

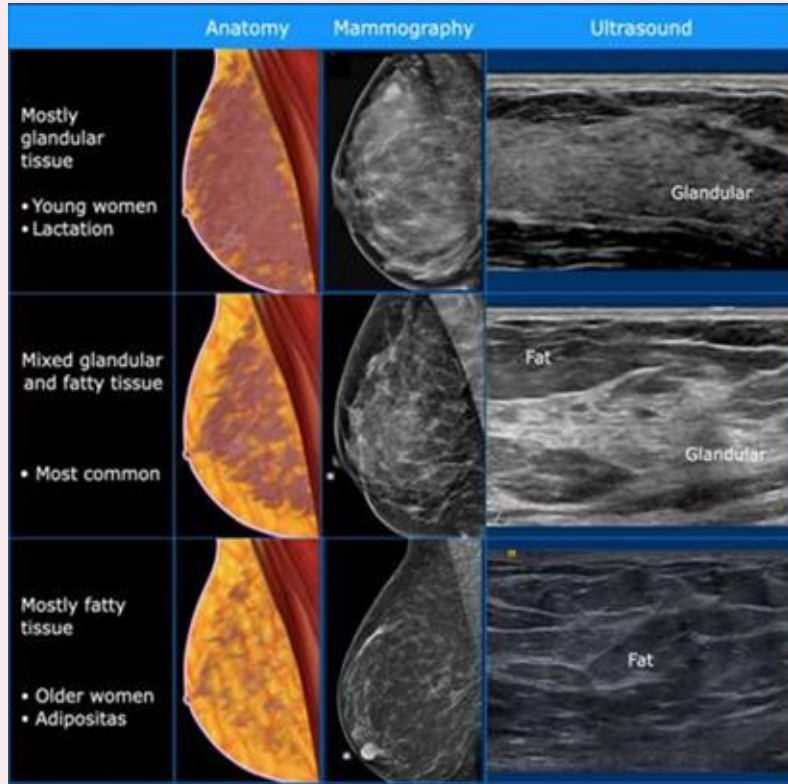
High-risk screening (BRCA), occult primary, dense breasts with discordant findings, evaluation of extent in known cancer, post-implant.

BI-RADS reporting categories

Cat	Interpretation	Action
0	Incomplete	Further imaging
1	Negative	Routine screening
2	Benign	Routine screening
3	Probably benign	6-month follow-up
4	Suspicious	Biopsy
5	Highly suggestive of malignancy	Biopsy + workup
6	Known biopsy-proven cancer	Treatment

Cat 4 & 5 → core needle biopsy is mandatory.

1) Ultrasound



Normal breast on US

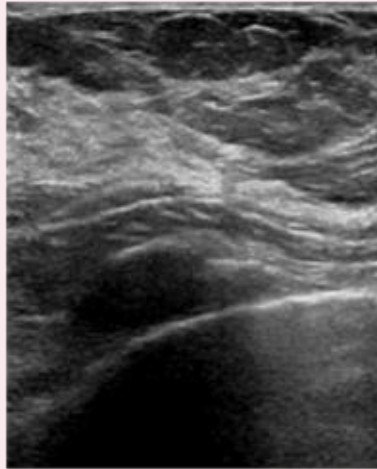
Cyst	Fibroadenoma	Cancer	Glandular tissue
Anechoic pattern	Hypoechoic	Hypoechoic	Hyperechoic
Oval or round shape	Most common: • oval or round Less frequent: • lobulated	Most common: • irregular shape Less frequent: • round or oval	Locally prominent glandular tissue
Circumscribed margin	Circumscribed margin	Margin is not circumscribed: • Indistinct • angular • microlobulated • spiculated	
Horizontal orientation	Horizontal orientation	Vertical orientation	
Posterior Enhancement	Sometimes minimal posterior enhancement	Frequently posterior shadowing	No feature
No calcifications	May have gross calcifications	May have small calcifications in or outside mass	No

Common breast pathology US

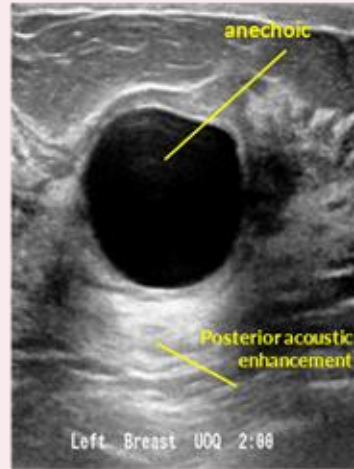
Further readings: <https://radiologyassistant.nl/breast/ultrasound/ultrasound-of-the-breast>

1) Ultrasound

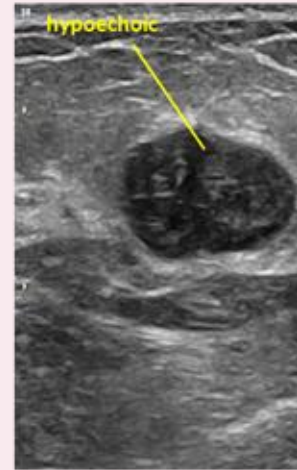
- Initial investigation for young patient age <35 years old because younger patient has dense breast with less fatty tissue hence it is hard to recognize lesion using mammogram
- To distinguish solid lesions (cancerous or benign) from cysts
- To localise impalpable lesions
- To guide procedures such as percutaneous needle biopsies and cyst aspiration



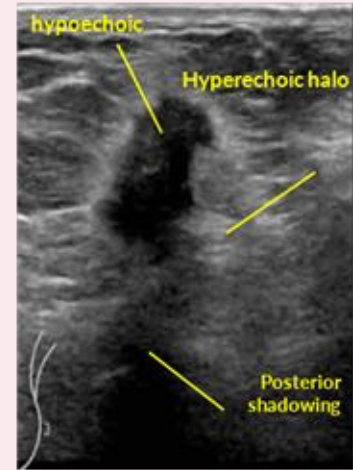Normal breast



Breast cyst



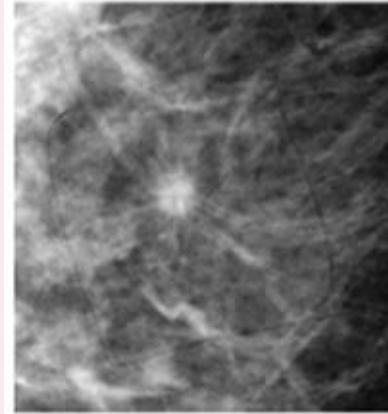
Fibroadenoma



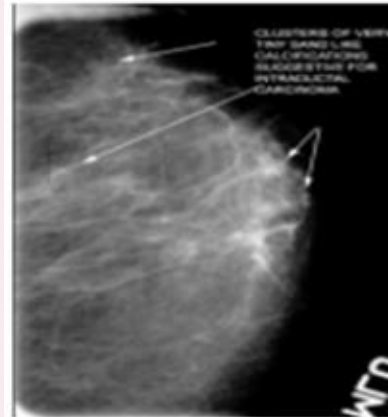Breast cancer

2) Mammogram

- Initial investigation for patient age >35 years old, sensitivity increasing with age as the breast is less dense
- To analyse mass, calcification or area of abnormal density that may indicate the presence of cancer
- Possible findings of breast cancer in mammogram :
 - **Stellate appearance, spiculated border (pathognomonic)**
 - Microcalcification, ill-defined border
 - Architectural distortion

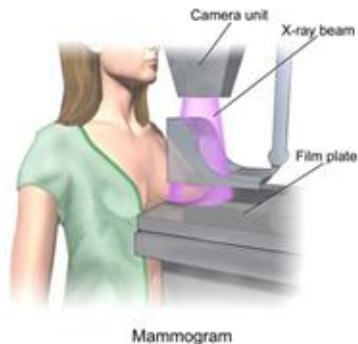
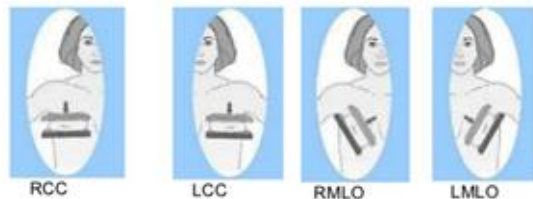


Stellate appearance



Microcalcification

2) Mammogram



Two standard view of mammogram:

- Craniocaudal
- Mediolateral oblique - to view axillary Ln

Final Assessment Categories			
Category	Management	Likelihood of Cancer	
0	Need additional imaging or prior examinations	Recall for additional imaging and/or await prior examinations	Not applicable
1	Negative	Routine screening	Essentially 0%
2	Benign	Routine screening	Essentially 0%
3	Probably benign	Short interval follow-up (six months) or continued surveillance	>0% but ≤2%
4	Suspicious	Tissue diagnosis	4a. low suspicion of malignancy (>2% to ≤10%) 4b. moderate suspicion of malignancy (>10% to ≤50%) 4c. high suspicion of malignancy (>50% to <95%)
5	Highly suggestive of malignancy	Tissue diagnosis	≥95%
6	Known biopsy-proven	Surgical excision when clinical appropriate	Not applicable

Biopsy

Tissue diagnosis — core needle biopsy is preferred

FNAC

Fine needle aspiration cytology

Pros

- Quick, cheap
- Useful for cysts (aspirate to dryness)
- Differentiate solid/cystic

Cons

- Cytology only — no architecture
- Cannot assess invasion
- Operator-dependent

When to use

Symptomatic cysts; cytology of nodes

Core Needle Biopsy ^{PREFERRED}

CNB — 14G under USG guidance

Pros

- Histology + receptor status
- Distinguishes in-situ vs invasive
- Standard of care

Cons

- Bigger needle, may need LA
- Small risk of haematoma

When to use

ANY suspicious solid lesion

Excisional / VAB

Open biopsy or vacuum-assisted

Pros

- Removes lesion entirely
- VAB good for microcalcifications

Cons

- More invasive
- Cosmetic outcome
- Reserved for selected cases

When to use

When CNB inconclusive / discordant

Differential Diagnosis

Common causes shift dramatically with age

< 30 years

Young patient

- Fibroadenoma (most common)
- Breast cyst
- Fibrocystic change
- Phyllodes tumour (rapid growth)
- Lactational changes / mastitis
- Breast abscess

Cancer rare but not zero — never dismiss.

30 – 50 years

Reproductive age

- Fibrocystic change
- Cysts (often multiple)
- Fibroadenoma (involuting)
- Duct ectasia
- Fat necrosis (trauma, post-op)
- Carcinoma — rising incidence

Triple assessment is mandatory.

> 50 years

Post-menopausal

- Invasive ductal carcinoma
- Invasive lobular carcinoma
- DCIS
- Paget disease of nipple
- Metastasis (rare)
- Lipoma / sebaceous cyst

Treat as malignant until proven otherwise.

Benign vs Malignant

Clinical features — but never rely on these alone




Suggests BENIGN

- Young patient (< 30 years)
- Well-defined, smooth borders
- Soft to firm, rubbery consistency
- Highly mobile ("slips under fingers")
- Cyclical tenderness or pain
- Bilateral, multiple lumps
- No skin or nipple changes
- No axillary lymphadenopathy




Suggests MALIGNANT

- Older patient (> 40 years)
- Hard, irregular, ill-defined borders
- Fixed to skin or chest wall
- Painless (usually)
- Skin dimpling, peau d'orange, ulceration
- Nipple retraction, bloody discharge
- Axillary or supraclavicular nodes
- Constitutional symptoms / mets symptoms

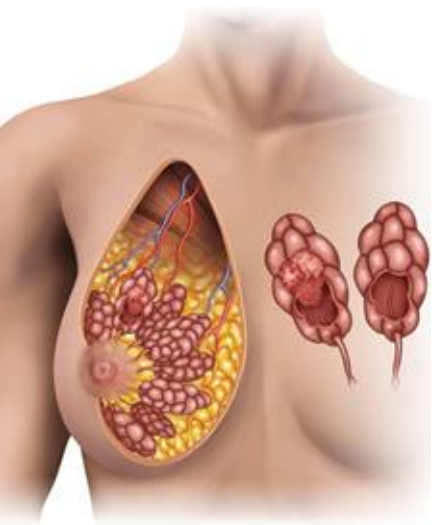


BENIGN BREAST DISEASE

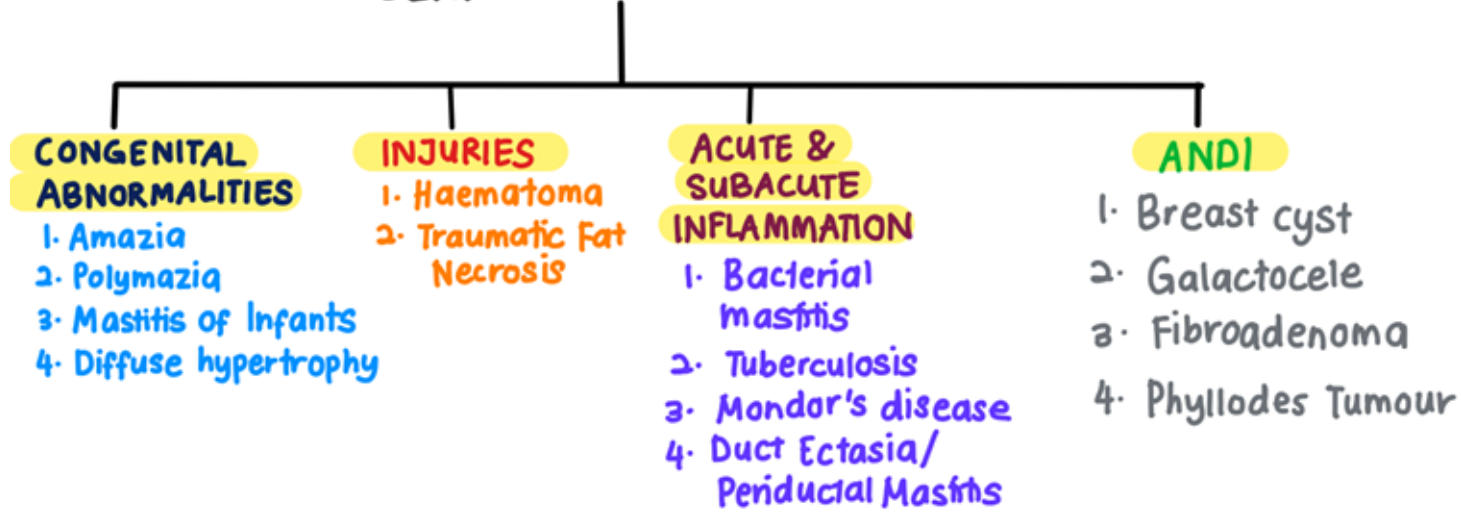


BENIGN BREAST DISEASE

- Up to 30% of women will suffer from a benign breast disorder.
- The most common symptoms are **pain, lumpiness or a lump.**
- The aim of treatment is to **exclude cancer & to treat any remaining symptoms.**
- Benign breast disease includes
 - Congenital abnormalities
 - Injuries of the breast
 - Acute & subacute inflammations of the breast
 - Aberration of normal development & involution (ANDI)



BENIGN BREAST DISEASE



1. CONGENITAL ABNORMALITIES

Amazia	Polymazia
<ul style="list-style-type: none">• Congenital absence of the breast on one or both sides• Sometimes associated with absence of the sternal portion of the pectoralis major (Poland's syndrome)• More common in males	<ul style="list-style-type: none">• Accessory breasts• In axilla (most frequent), groin, buttock & thigh.• Known to function during lactation

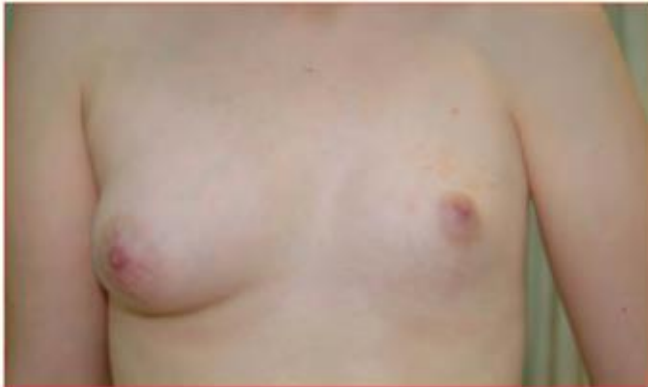

Figure 53.11 Congenital absence of the left breast.

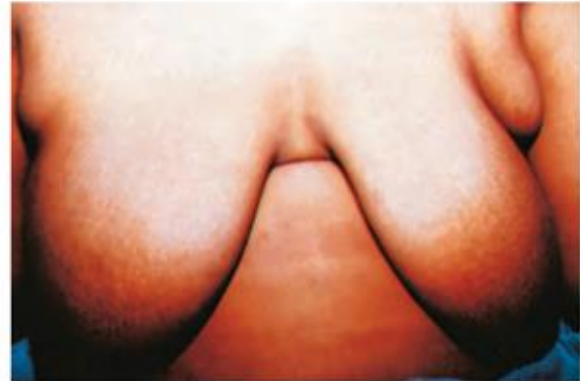
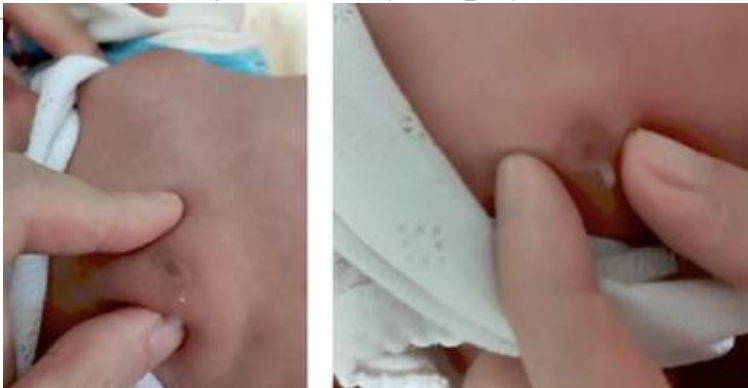
Figure 53.12 Bilateral accessory breasts.

1. CONGENITAL ABNORMALITIES

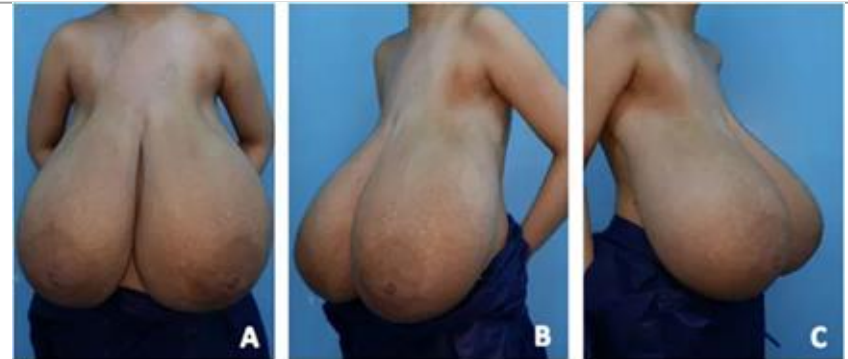
Mastitis of Infants

- Seen only in full term infants
- Slight milky secretion from the breast of infants when nipple is pressed, disappears during the third week.
- Caused by stimulation of the fetal breast by prolactin in response to the drop of maternal estrogens & is essentially physiology.
- True mastitis is uncommon & usually predominately caused by *Staphylococcus aureus*.



Diffuse Hypertrophy

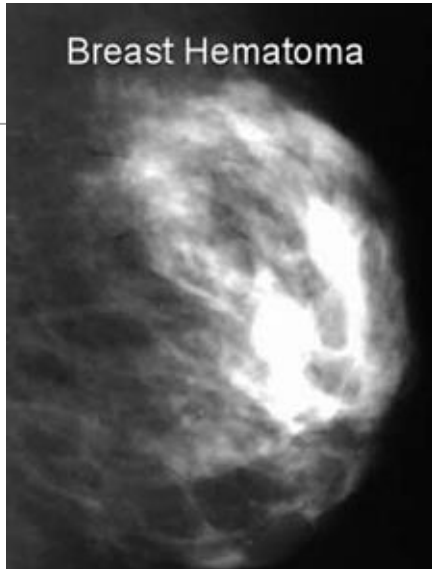
- Occurs sporadically in otherwise healthy girls at puberty & during first pregnancy.
- Commonly bilateral
- The tremendous overgrowth is caused by alteration in the normal sensitivity of the breast to estrogenic hormones.
- Treatment : anti-estrogen, reduction mammoplasty



2. INJURIES OF THE BREAST

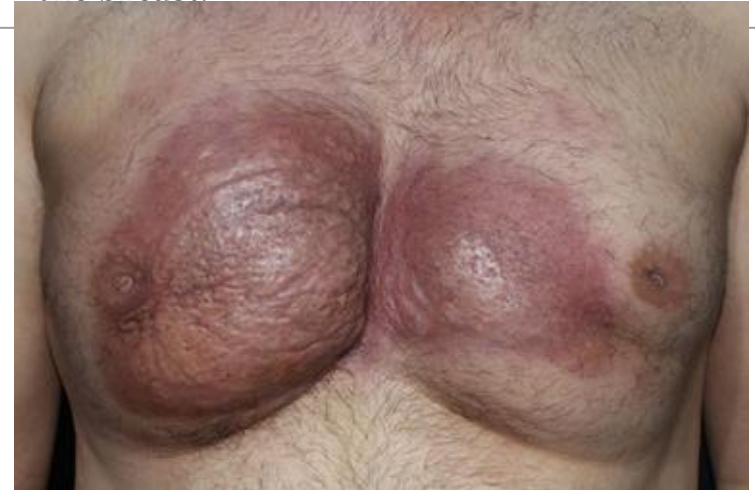Haematoma

- Particularly a resolving haematoma, giving rise to a lump which in the absence of overlying bruising
- Difficult to diagnose correctly unless biopsied



Traumatic Fat Necrosis

- Occurs in stout, middle aged women
- Following a blow, or indirect violence
- There is focal necrosis of fatty tissue with local scarring & possibly skin tethering
- Appears as a painless lump
- The condition resolves spontaneously although some cases may leave a permanent scar within the breast.



3. ACUTE & SUBACUTE INFLAMMATIONS OF THE BREAST

Bacterial Mastitis

- Associated with lactation in majority cases

Aetiology

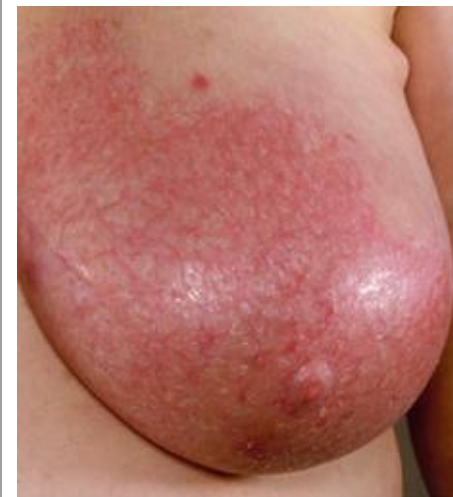- Lactation mastitis most are caused by *S. aureus* (50% of infants harbour staphylococci in the nasopharynx)
- Ascending infection from a sore & cracked nipple
- Lactiferous duct will become blocked by epithelial debris → stasis of milk → staphylococci cause clotting of milk → organisms multiply within clot

Clinical Features

- Classical signs of acute inflammation
- Generalised cellulitis → abscess

Treatment

1. Cellulitic stage
 - a. Give antibiotic (flucloxacillin/co-amoxiclav)
 - b. Continue breastfeeding if tolerated
 - c. Support of the breast, local heat & analgesia to relieve pain
2. Breast should be incised & drained if the infection did not resolve within 48 hours or if after being emptied of milk there was an area of tense induration/evidence of underlying abscess.
 - a. Perform repeated aspirations under antibiotic cover
 - b. Presence of pus can be confirmed with needle aspiration & the pus should be sent for culture.



© BMJ FOUNDATION FOR MEDICAL EDUCATION AND RESEARCH. ALL RIGHTS RESERVED.

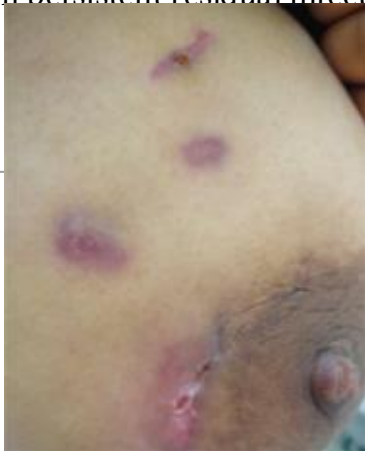O'Connell, P.R., McCaskie, A.W., & Williams, N.S. (Eds.). (2018). Bailey & Love's Short Practice of Surgery, 27th Edition (27th ed.). CRC Press.

<https://doi.org/10.1201/9781315111087>

3. ACUTE & SUBACUTE INFLAMMATIONS OF THE BREAST

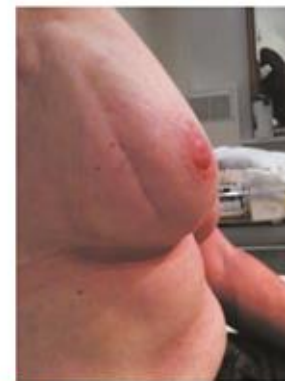Tuberculosis of The Breast

- Usually associated with active pulmonary tuberculosis or tuberculous cervical adenitis
- Most often in parous women & usually presents with multiple chronic abscesses & sinuses and a typical bluish, attenuated appearance of the surrounding skin.
- The diagnosis rests on bacteriological & histological exam.
- Treatment is with anti-TB chemotherapy
- Healing is usual, mastectomy should be restricted to patients with persistent residual infection



Mondor's Disease

- Thrombophlebitis of the superficial veins of the breast & anterior chest wall.
- Usually idiopathic but may be triggered by trauma, inflammation or very rare linked to a malignancy elsewhere.
- The pathognomonic feature is a thrombosed subcutaneous cord, usually attached to the skin.
- When the skin over the breast is stretched by raising the arm, a narrow, shallow, subcutaneous groove alongside the cord becomes apparent.
- The only treatment required is to restrict arm movements & may benefit from topical NSAIDs.
- Usually subsides within few months without recurrence, complications or deformity.



3. ACUTE & SUBACUTE INFLAMMATIONS OF THE BREAST

Duct Ectasia/Periductal Mastitis

Pathology

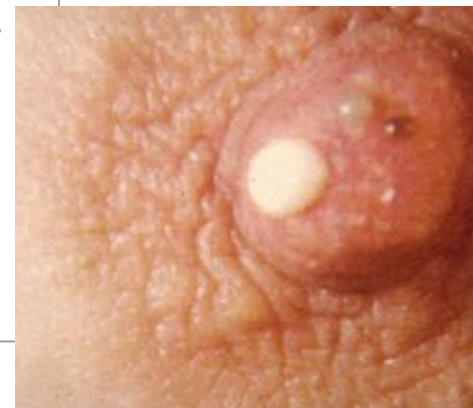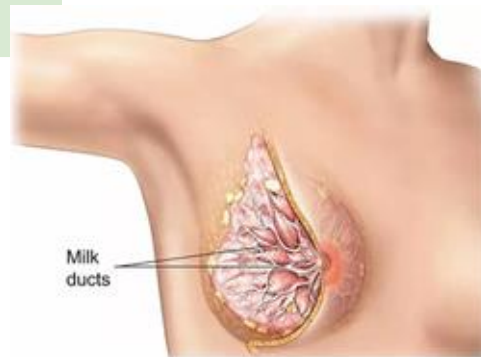
- Dilatation of the breast ducts, often a/w periductal inflammation.
- Much common in smokers
- The classical description: Dilatation in 1/more of the larger lactiferous ducts which filled with a stagnant brown/green secretion → leads to periductal mastitis/abscess & fistula formation

Clinical Features

- Nipple discharge (of any colour)
- Subareolar mass, abscess, mammary duct fistula and/or nipple retraction

Treatment

- In case of mass/nipple retraction, carcinoma must be excluded by obtaining mammogram & negative cytology or histology.
- Give antibiotic therapy (co-amoxiclav/flucloxacillin & metronidazole)
- Definitive is excision of all the major ducts (Hadfield's operation)



CHRONIC INFLAMMATION

Chronic Granulomatous Mastitis

- CGM is a chronic inflammatory disorder affecting the breast of unknown aetiology.

Aetiology

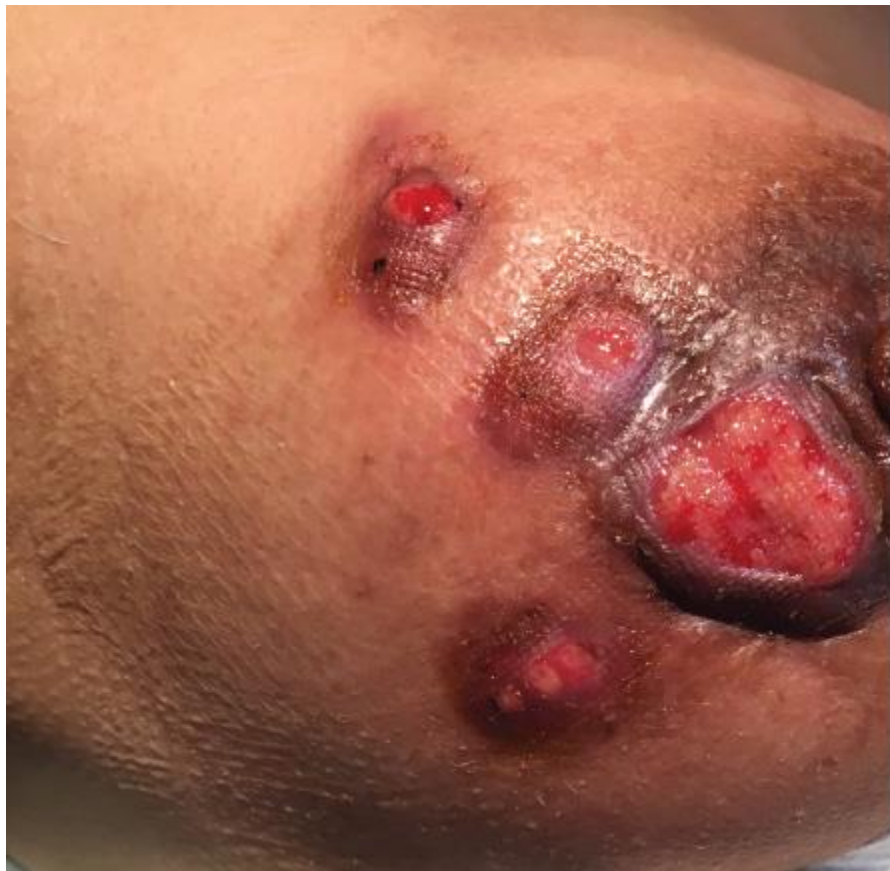- Autoimmune, hormonal and infectious pathophysiologies have been proposed but not substantiated. Patients are young, parous women in the childbearing age group usually but not exclusively with a history of recent lactation.

Clinical Features

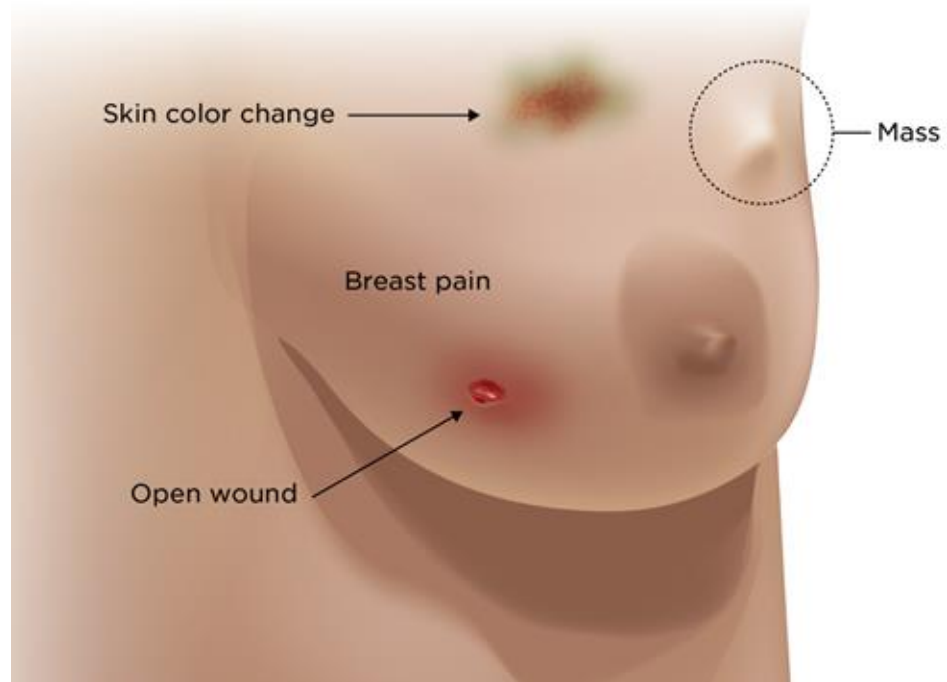
- Clinically it can mimic breast cancer presenting as a painless, firm to hard mass with overlying skin changes including erythema, ulceration, sinus tract formation and nipple retraction. It may also present as recurrent breast abscesses. Axillary lymphadenopathy is seen in 15% of cases

Treatment

1. Antibiotics should be prescribed according to sensitivities
2. Medical treatment with oral steroids can attain remission in over 60% of case
3. Surgery is indicated in cases with co-existing abscess formation which needs drainage and treatment with antibiotics prior to initiation of steroids.



Idiopathic Granulomatous Mastitis



4. ABERRATIONS OF NORMAL DEVELOPMENT & INVOLUTION (ANDI)

Aetiology

- Breast is a dynamic structure that undergoes changes throughout woman's reproductive life & superimposed upon this, cyclical changes throughout the menstrual cycle.
- The pathogenesis of ANDI involves disturbances in the breast physiology extending from a perturbation of normality to well defined disease processes.

Pathology

Cyst formation	Inevitable & vary in size
Fibrosis	Fat & elastic tissues disappear & are replaced with dense white fibrous trabeculae
Hyperplasia	Of the epithelium in the lining of the ducts & acini
Papillomatosis	The epithelial hyperplasia may be so extensive that it results in papillomatous overgrowth within the ducts.

Clinical Features

- A benign discrete lump in the breast is commonly a cyst or fibroadenoma.
- Lumpiness may be bilateral, commonly in upper outer quadrant. The changes may be cyclical with an increase in both lumpiness & often tenderness before a menstrual period.
- Non cyclical mastalgia is more common in perimenopausal women. May be a/w ANDI or with periductal mastitis.

BREAST CYST

- Most commonly in the last decade of reproductive life as a result of a non integrated involution of stroma & epithelium
- Multiple, bilateral & can mimic malignancy
- Diagnosis by aspiration and or ultrasound
- Treatment
 - Small = aspirate
 - If there is a residual lump or if the fluid is blood stained, a core biopsy/local excision for histological diagnosis is advisable.

GALACTOCELE

- Usually presents as a solitary, subareolar cyst and always dates from lactation.
- Contains milk & in long standing cases its walls tend to calcify

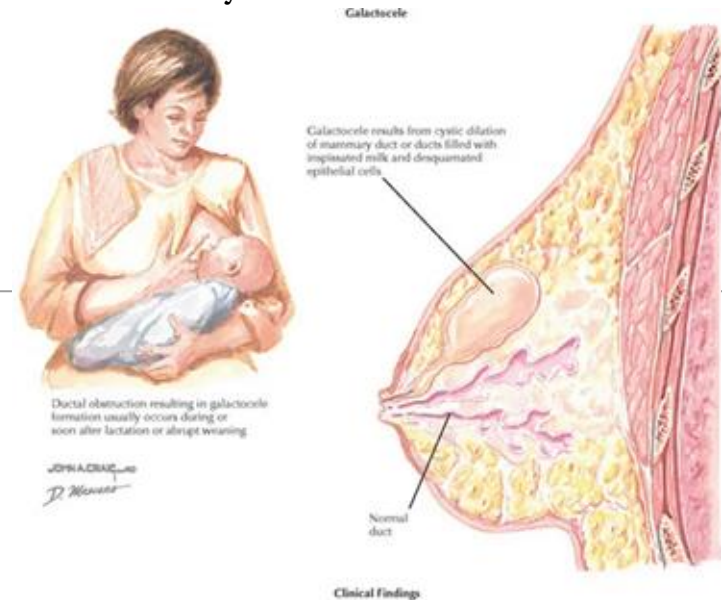

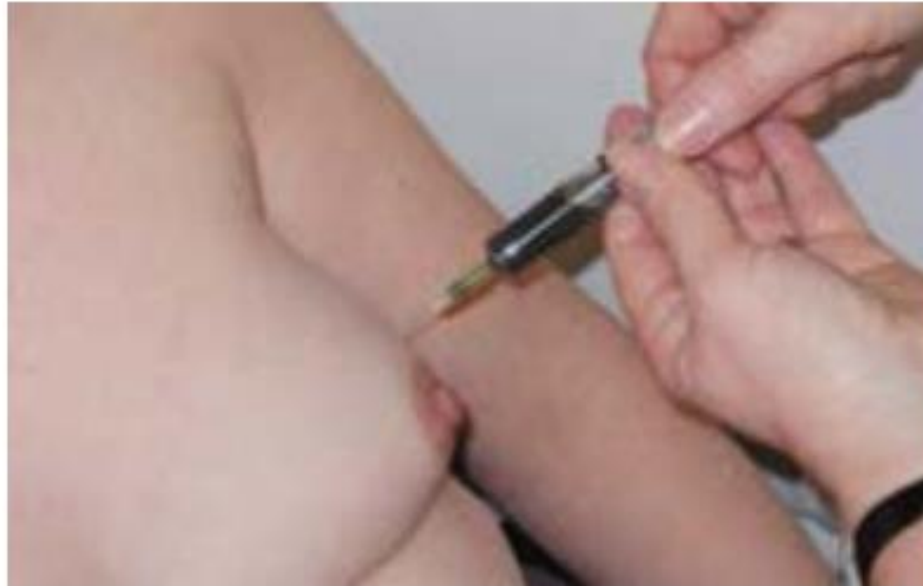


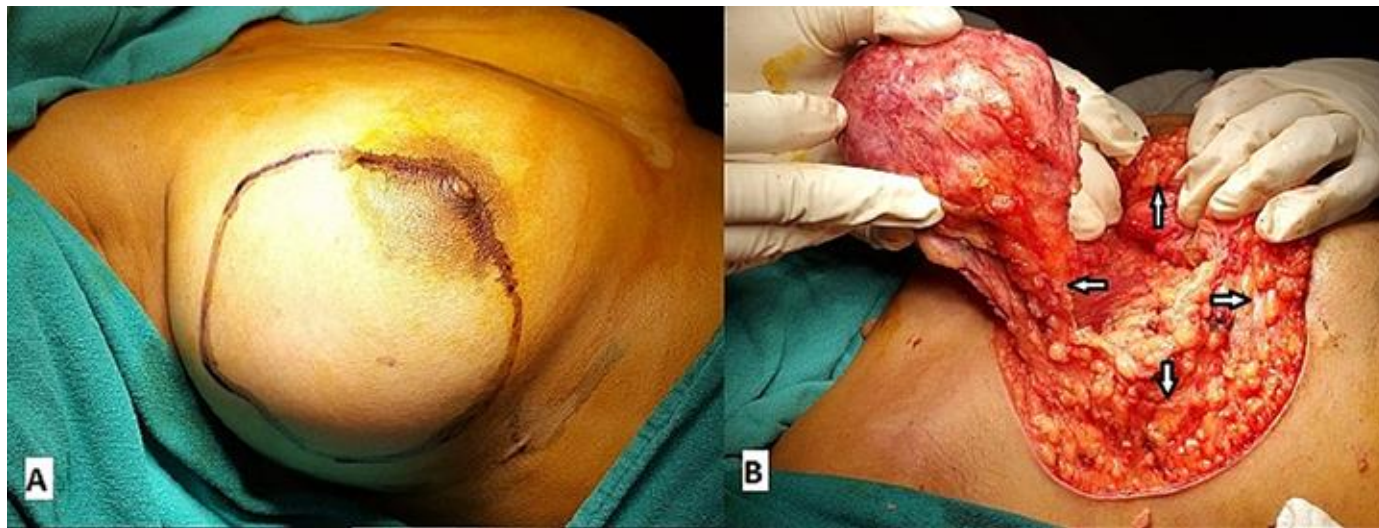
Figure 13.9 Aspiration of a breast cyst, although this would normally be performed under ultrasound guidance. The aspirate has the typical brownish–green colour seen with a benign cyst.

FIBROADENOMA

- Arise in the fully developed breast between the ages of 15 and 25, although occasionally occur in much older women
- Arise from hyperplasia of a single lobule & usually grow up to 2-3 cm in size
- Surrounded by a well marked capsule
- Does not require excision unless associated with suspicious cytology
- Alternatives to surgery include cryoablation, heating with high frequency ultrasound (echotherapy) or removal with a large core vacuum biopsy system.

O/E

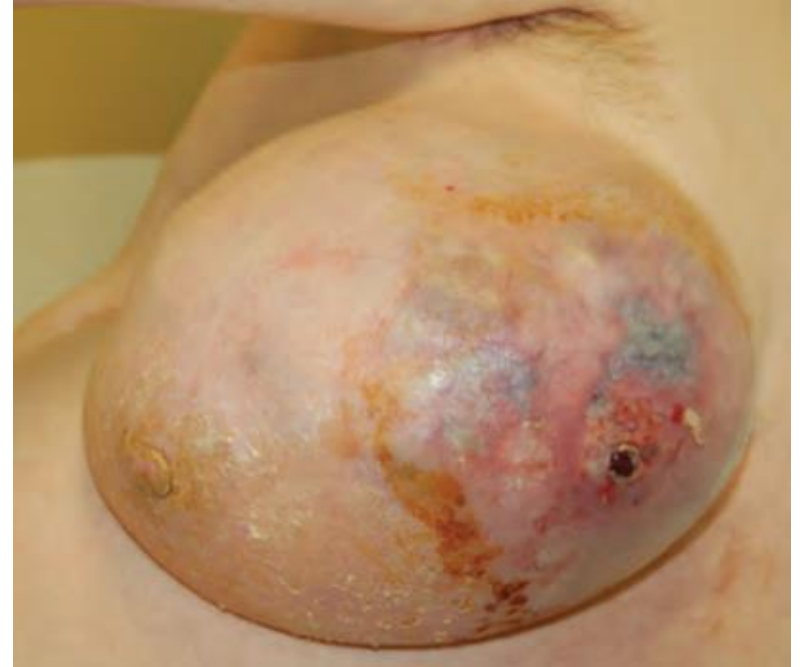Position	May be anywhere in the breast
Shape & size	Usually spherical or ovoid but sometimes lobulated & may be in any size
Surface	Smooth, the edge definite & the consistency like firm rubber
Mobility	Most mobile of all breast lesions & fully merits the description 'breast mouse'



- A. Giant fibroadenoma in the outer quadrant of the right breast.
B. Well-defined lump excised in total (defect area marked with white arrows).

PHYLLODES TUMOUR

- Benign tumours, previously sometimes known as serocystic disease of Brodie or cytosarcoma phyllodes.
- Usually occur in women >40 years
- Present as a large tumour with an unevenly bosselated surface.
- Ulceration of overlying skin occurs because of the pressure necrosis.
- Mobile on the chest wall.
- Treatment - enucleation in young women & wide local excision (benign type)
- Massive tumours, recurrent tumours and those of the malignant type require mastectomy.



A light pink ribbon is centered on a darker pink background. The ribbon is tied in a loop at the top, with two long tails extending downwards and outwards. The text "BREAST CANCER" is superimposed over the center of the ribbon.

BREAST CANCER

EPIDEMIOLOGY

(References: Malaysia National Cancer Registry Report 2012-2016)

#1

Most common cancer in Malaysian women

MNCR 2017-2021

1:19

Lifetime risk for Malaysian women

Higher in Chinese ethnicity

50%

Present at Stage III / IV

Late presentation remains
a problem

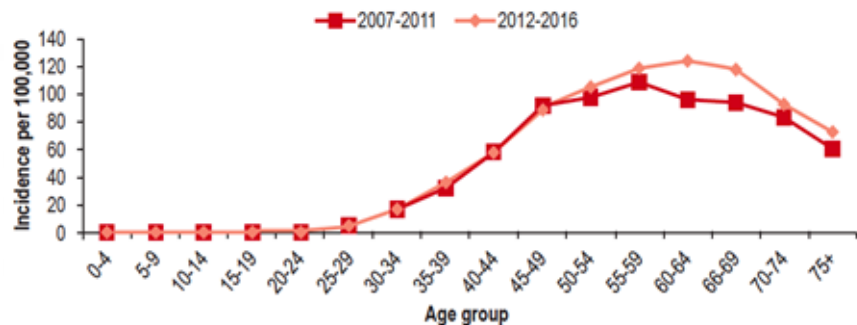


Figure 1. Female breast cancer: comparison of age-specific incidence rate by year in Malaysia

Peak incidence: 40-60years

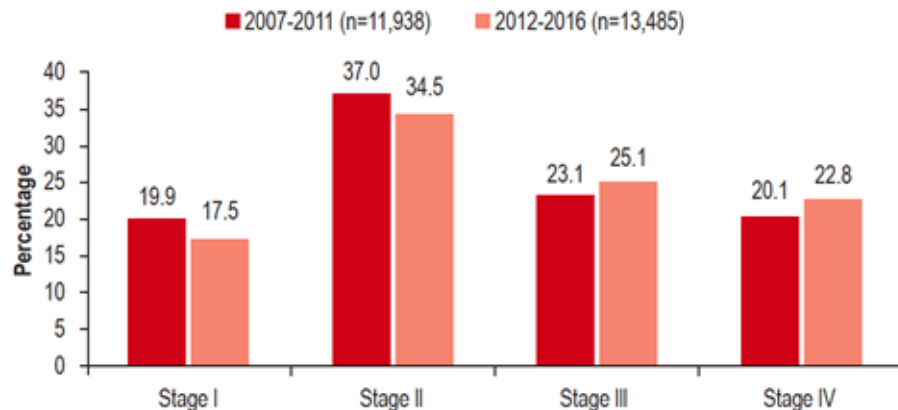


Figure 2. Female breast cancer: comparison of staging percentage by year in Malaysia

RISK FACTORS

(References: CPG Management of Breast Cancer 3rd Edition)

Table 3: Stratifications of Risk Factors

Low Risk (RR 1.0 - 1.4)	Moderate Risk (RR 1.5 - 2.0)	High Risk (RR > 2.0)
<ul style="list-style-type: none"> Alcohol consumption 	<ul style="list-style-type: none"> Increasing age from 40 years old 	<ul style="list-style-type: none"> Personal history of invasive breast cancer
<ul style="list-style-type: none"> Reproductive factors: <ul style="list-style-type: none"> Increasing age at first full term pregnancy > 30 year Hormone replacement therapy Oral contraceptive pill usage 	<ul style="list-style-type: none"> Reproductive factors: <ul style="list-style-type: none"> Early menarche (< 12 year old) (RR 1.02) Late menopause (> 55 year old) (OR 2.4) Nulliparity 	<ul style="list-style-type: none"> Lobular Carcinoma In Situ (LCIS) and Ductal Carcinoma In Situ (DCIS)
<ul style="list-style-type: none"> Obesity 	<ul style="list-style-type: none"> Benign breast disease with proliferation without atypia 	<ul style="list-style-type: none"> Benign breast disease with atypical hyperplasia
	<ul style="list-style-type: none"> Dense breast 	<ul style="list-style-type: none"> Ionising radiation from treatment of breast cancer, Hodgkin's disease, etc.
		<ul style="list-style-type: none"> Carrier of BRCA1 and 2 genetic mutation
		<ul style="list-style-type: none"> Significant family history i.e. first degree family with breast cancer

SCREENING

- For local setting, breast cancer screening is based on the risk of developing the cancer:
 - general population - women with:⁵
 - no personal history of breast cancer
 - no strong family history of breast cancer
 - Individuals with high risk of developing breast cancer:^{5;18, level III}
 - BRCA mutation
 - first-degree relatives of BRCA carrier who have not been tested
 - history of chest irradiation at young age
 - personal history(s) of breast cancer
 - strong family history of breast or ovarian cancer
 - first degree relatives: mother, father, siblings, children
 - second degree relatives: grandparents, aunts, uncles, nieces, nephews

Recommendation 1

- Screening mammography may be performed biennially in women aged 50 - 74 years in the general population.
- For women of moderate risk, screening mammography may be performed annually from 40 - 49 years of age, annually or biennially from 50 - 59 and biennially from 60 onwards.
- For women of high risk of breast cancer, where no genetic variant has been identified, screening mammography may be considered from 30 - 39 years of age, performed annually from 40 - 59 and biennially from 60 onwards.
- For carriers of pathogenic or likely pathogenic variants in BRCA1, BRCA2 and PALB2, annual MRI should be offered from 30 - 49 years of age, annual mammography from 40 - 69 and biennial mammography from 70 onwards.

Table 7. Summary of recommendations on screening for women with no personal history of breast cancer

Age (years)	Average risk of breast cancer ¹	Moderate risk of breast cancer ²	High risk of breast cancer (but with a 30% or lower probability of being a BRCA or TP53 carrier) ³	Known BRCA1 or BRCA2 carrier
20 - 29	Do not offer mammography	Do not offer mammography	Do not offer mammography	Do not offer mammography
	Do not offer MRI	Do not offer MRI	Do not offer MRI	Do not offer MRI
30 - 39	Do not offer mammography	Do not offer mammography	Consider annual mammography	Annual MRI and consider annual mammography
	Do not offer MRI	Do not offer MRI	Do not offer MRI	
40 - 49	Do not offer mammography	Annual mammography	Annual mammography	Annual mammography and annual MRI
	Do not offer MRI	Do not offer MRI	Do not offer MRI	
50 - 59	Mammography as part of population screening	Consider annual mammography	Annual mammography	Annual mammography
	Do not offer MRI	Do not offer MRI	Do not offer MRI	Do not offer MRI unless dense breast
60 - 69	Mammography as part of population screening	Mammography as part of population screening	Mammography as part of population screening	Annual mammography
	Do not offer MRI	Do not offer MRI	Do not offer MRI	Do not offer MRI unless dense breast
70+	Mammography as part of population screening	Mammography as part of population screening	Mammography as part of population screening	Mammography as part of population screening

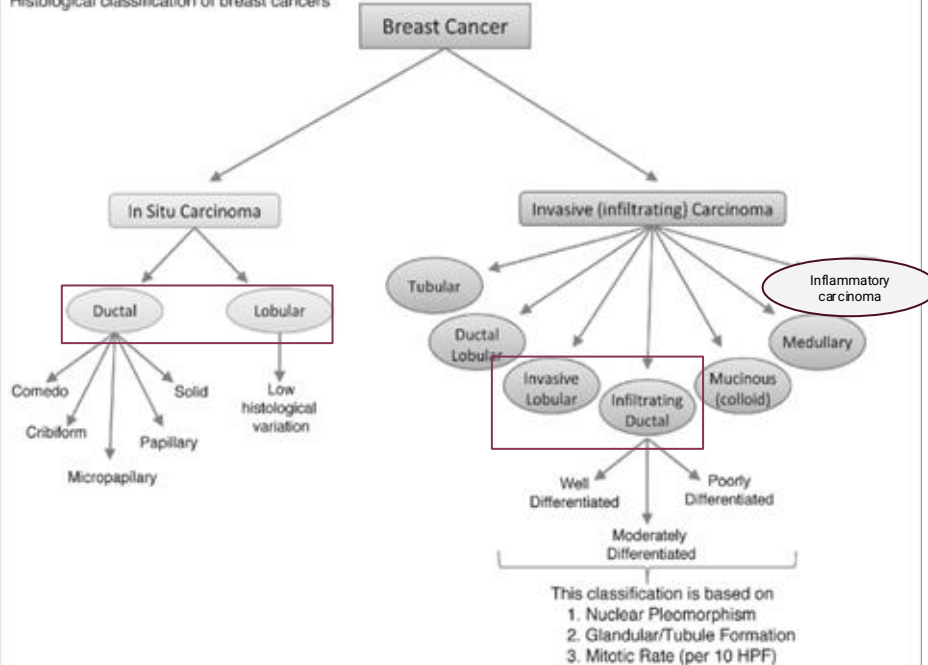
¹Lifetime risk of developing breast cancer is <17%.

²Lifetime risk of developing breast cancer is at least 17% but <30%. This is likely to include individuals with pathogenic/likely pathogenic variants in PALB2 regardless of family history of breast cancer and, individuals with pathogenic/likely pathogenic variants in ATM and CHEK2 and at least one first

CLASSIFICATION OF BREAST CA

Histological Classification

Histological classification of breast cancers

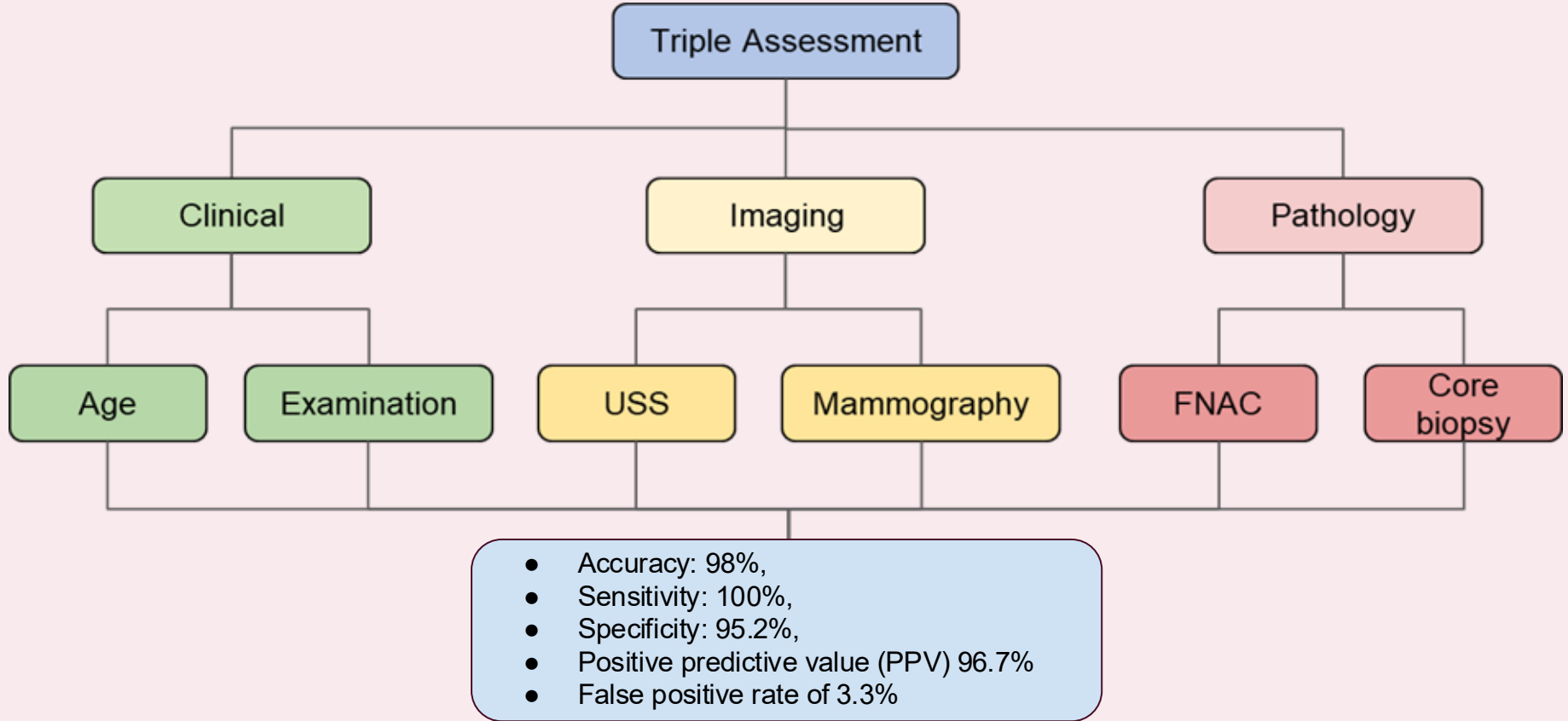


Molecular Classification

St. Gallen classification (2011)

Molecular subtypes of breast cancer
Luminal A
Luminal B with HER2 negative
Luminal B with HER2 positive
HER2 enriched
Basal-like (triple negative)*

ASSESSMENT AND DIAGNOSIS



(References: CPG Management of Breast Cancer 2nd Edition & 3rd Edition)

Staging in Early breast Cancer

- Chest radiograph, bone scan, liver ultrasonography and computerised tomography (CT) scan

CPG Recommendations

- If asymptomatic, routine imaging screening for metastasis should not be performed
- If signs and symptoms of lung, liver and bone metastases, or abnormal related laboratory tests, routine imaging investigations should be performed
- If localised bone pain, elevated alkaline phosphatase or symptoms suggestive of bone metastases, bone scintigraphy should be used if plain radiography or computed tomography staging is negative

Imaging for Staging

- CT TAP
- PET CT (depending on center availability)
- MRI spine (symptoms of malignant spinal cord compression)
- CT /MRI Brain (suspecting brain mets)

TNM STAGING

Determine the disease stage and prognosis to guide management

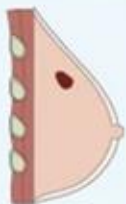

TNM staging based on :

1. The extent of tumour (T)
2. The spread to lymph nodes (N)
3. The presence of metastasis (M)

T

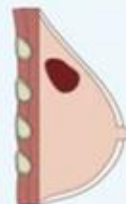T-1
Tumor <2cm



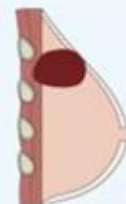T-2
Tumor 2-5cm



T-3
Tumor >5cm

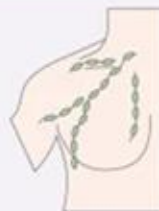

T-4
Tumor extends to skin or chest wall

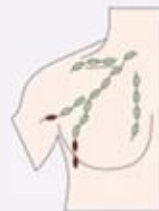

N

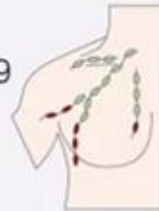N-0
No lymph node (LN) metastasis



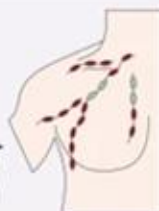N-1
Metastasis to 1-3 axillary (AX) LN



N-2
Metastasis to 4-9 AX or internal mammary (IM) LN

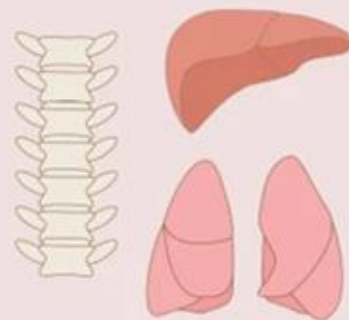


N-3
Metastasis to >10 AX or IM or infraclavicular or supraclavicular LN

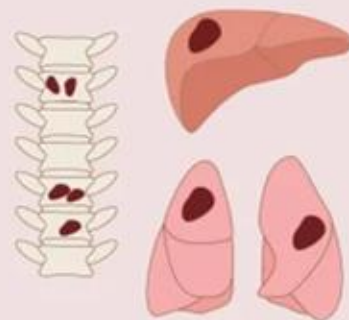


M

M-0
No distant metastasis



M-1
Distant metastasis

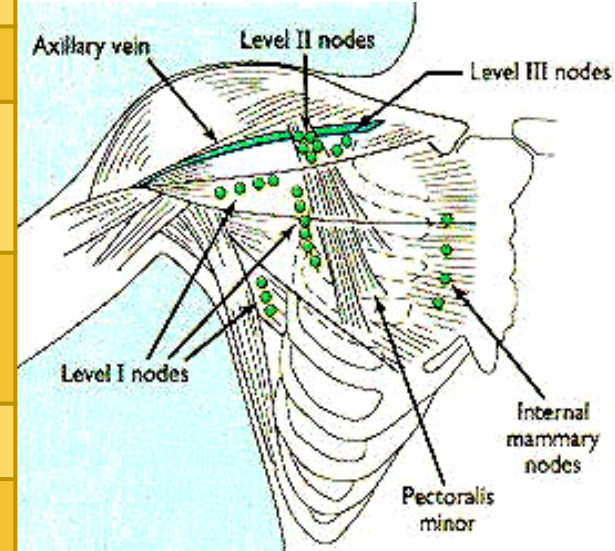


Definition of Primary Tumor (T)

TX	Primary tumour cannot be evaluated	
T0	No evidence of primary tumour	
Tis (CA in situ)	DCIS	Ductal Carcinoma In Situ
	LCIS	Lobular Carcinoma In Situ
	Paget's Disease	Paget's Disease of the nipple with no tumour
T1 (≤ 20 mm)	1a	> 1 mm - 5 mm
	1b	> 5 mm - 10 mm
	1c	> 10 mm - 20 mm
T2	> 20 mm - 50 mm	
T3	> 50 mm	
T4	4a	Extension to chest wall, invasion or adherence to pec muscle in absence of invasion of chest wall does not qualify.
	4b	Ulceration and/or ipsilateral macroscopic satellite nodules and/or edema (including peau d'orange) of the skin which does not meet criteria for inflammatory CA
	4c	4a and 4b
	4d	Inflammatory carcinoma

Definition of Regional Lymph Nodes (N)

NX	Regional lymph nodes cannot be evaluated	
N0	No regional lymph node involvement (by imaging or clinical examination)	
N1	Metastases to movable ipsilateral Level I, II axillary lymph node(s)	
N2	2a	Metastases in ipsilateral Level I, II axillary lymph nodes fixed to one another (matted) or to other structures
	2b	Metastases to ipsilateral internal mammary nodes in the absence of axillary lymph node metastases
N3	3a	Metastases in ipsilateral infraclavicular lymph nodes
	3b	Metastases in ipsilateral internal mammary lymph nodes and axillary lymph nodes
	3c	Metastases in ipsilateral supraclavicular lymph nodes.



Definition of Distant Metastasis (M)

M0	No clinical or radiographic evidence of distant metastasis
M1	Distant metastasis detected by clinical and radiographic means and/or histologically proven metastasis larger than 0.2 mm

Definition of Early Breast Cancer

Breast cancer that has not spread beyond breast or axillary lymph nodes

1. DCIS/LCIS (high grade)
2. Invasive:
 - Stage I
 - Stage IIA
 - Stage IIB

Stage	TNM
Stage 0	Tis, N0, M0
Stage IA	T1, N0, M0
Stage IB	T0, N1mi, M0 T1, N1mi, M0
Stage IIA	T0, N1, M0 T1, N1, M0 T2, N0, M0
Stage IIB	T2, N1, M0 T3, N0, M0
Stage IIIA	T0, N2, M0 T1, N2, M0 T2, N2, M0 T3, N1, M0 T3, N2, M0
Stage IIIB	T4, N0, M0 T4, N1, M0 T4, N2, M0
Stage IIIC	Any T, N3, M0
Stage IV	Any T, Any N, M1

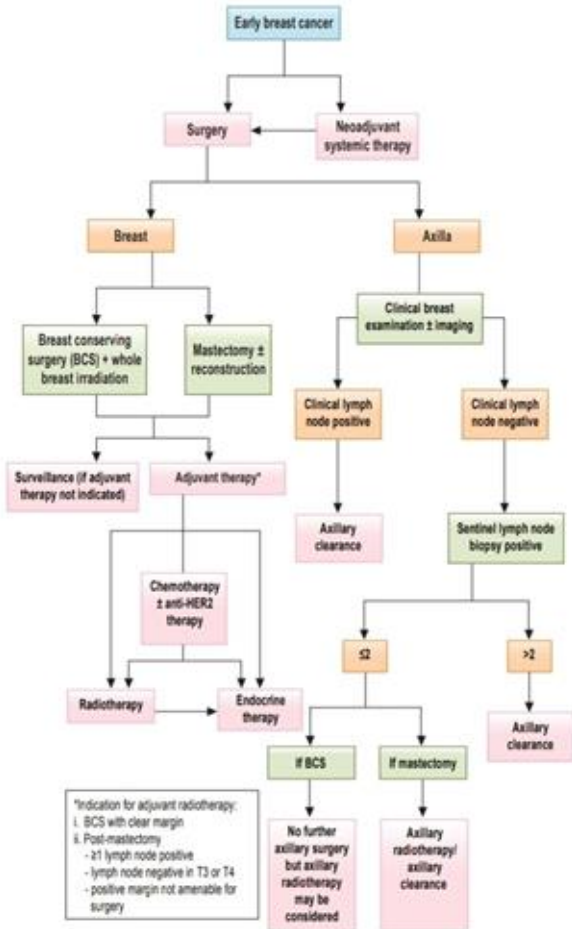
Management

To reduce the chance of local recurrence and the risk of metastatic spread

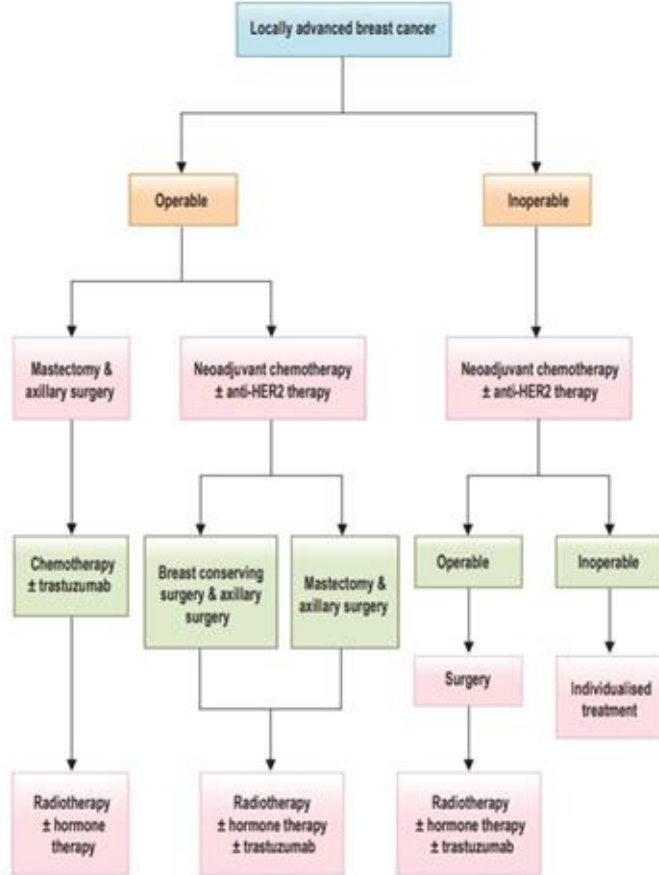


1. Surgical treatments
2. Adjunctive treatments

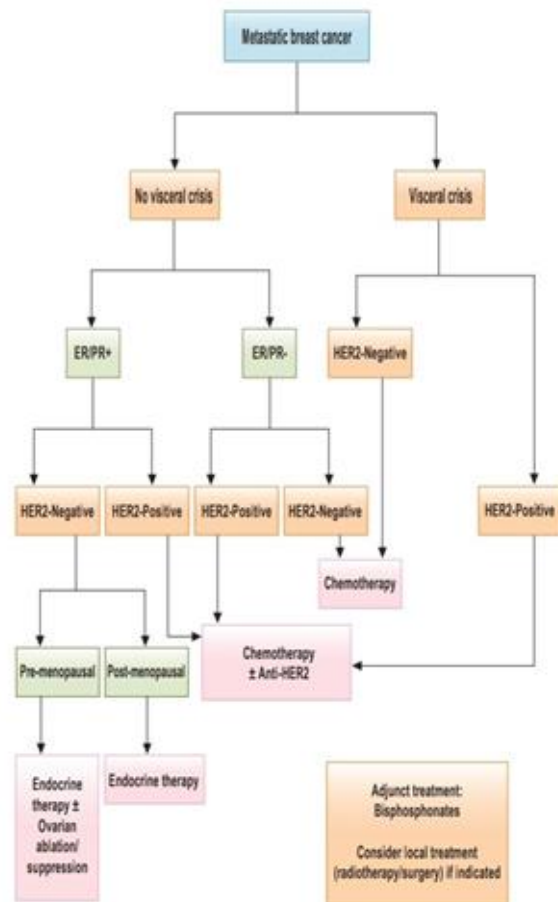
ALGORITHM 1. MANAGEMENT OF EARLY BREAST CANCER



ALGORITHM 2. MANAGEMENT OF LOCALLY ADVANCED BREAST CANCER

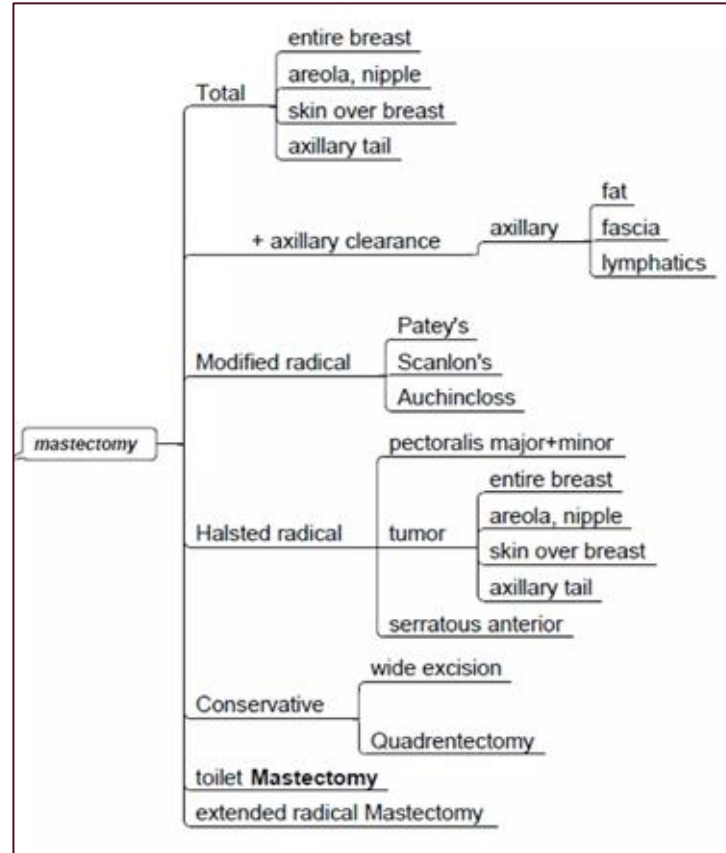


ALGORITHM 3. MANAGEMENT OF METASTATIC BREAST CANCER




Mastectomy


- Indicated for:
 - The tumour is **large (in relation to the size of breast)**
 - The tumour is situated closer to or **invades the nipple and areola**
 - Multifocal disease**, as is frequently found with lobular carcinoma
 - Local recurrence** in a breast that had previously been irradiated
 - Patient preference** (to avoid the need for radiotherapy and experience less long-term anxiety if the whole breast is removed rather than conserved)
- Modified radical Patey's mastectomy more commonly performed compared to Halsted radical mastectomy
- In Patey's, the breast and associated structures are dissected and the excised mass is composed of:
 - the whole breast;
 - a large portion of skin, the centre of which overlies the tumour but which always includes the nipple;
 - all of the fat, fascia and lymph nodes of the axilla.




Types of Mastectomies




TOTAL MASTECTOMY
A total mastectomy removes the entire breast, areola, nipple, and breast tissue.




MODIFIED RADICAL MASTECTOMY
A modified radical mastectomy and radical mastectomy are very similar with the differences being in the amount of lymph node tissue removed.



RADICAL MASTECTOMY
Radical mastectomy removes lymph node tissue more extensive than modified radical, and even goes as far as to remove some breast wall muscle tissue.



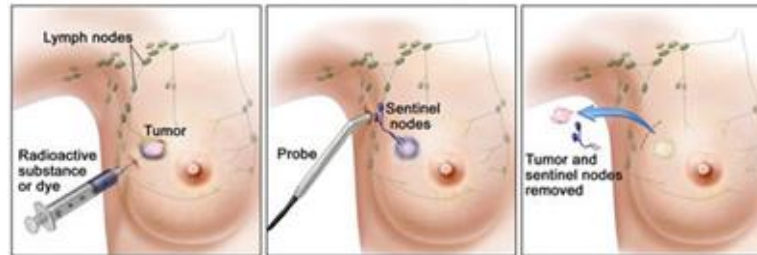
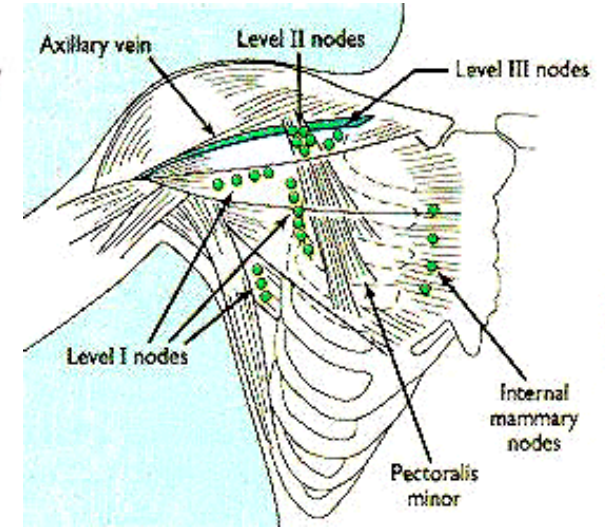
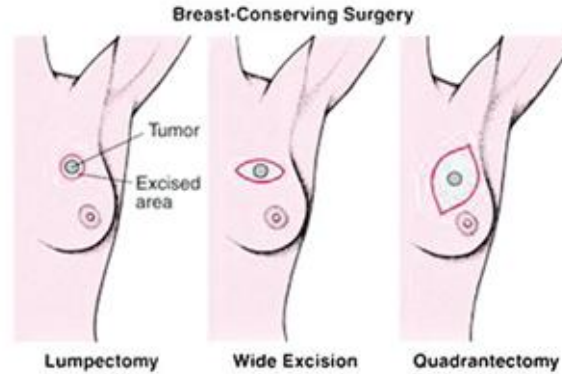
PARTIAL MASTECTOMY
A partial mastectomy is removal of a small quadrant or lump in the breast tissue, sparing the rest.



NIPPLE-SPARING MASTECTOMY
A nipple sparing mastectomy is just that removal of the tumor or breast tissue affected but sparing and saving the nipple.

Breast Conservative Surgery

- **Wide local excision** - removing the tumour plus a margin of normal breast tissue around it.
 - **Lumpectomy** - a benign tumour is excised and in which a large amount of normal breast tissue is not resected
 - **Quadrantectomy** - involves removing the entire segment of the breast that contains the tumour
- **MUST** be followed by radiotherapy
- Achieves an **acceptable cosmetic result**
- Usually combined with axilla surgery, usually via a separate incision in the axilla
- Preoperative evaluation of axillary LN separates patients into two categories :
 - Patients with clinically negative nodes (N0) undergo **sentinel lymph node biopsy (SLNB)**
 - Patients with clinically positive nodes undergo **axillary lymph node dissection (ALND)**



Axillary lymph node dissection (ALND)

- Incision is made under the arm and lymph nodes from **Level I** and **Level II** are removed (**Level III** lymph nodes are not usually removed because this does not improve survival)
- **Level III** lymph nodes will be removed if the cancer has spread to the lymph nodes and formed a lump in the armpit or if bigger nodes are seen on imaging tests

Adjuvant Radiation Therapy (RT)

- The purpose of adjuvant radiation therapy (RT) is to;
 - Eradicate any tumor deposits remaining following surgery
 - Reduces risk of locoregional recurrence and improves breast cancer-specific and overall survivals
- Radiotherapy to the chest wall after mastectomy is indicated in selected patients in whom the risks of local recurrence are high
 - Large tumour > 4 cm in diameter
 - A grade 3 tumour
 - Axillary lymph node involvement
 - Presence of vascular invasion
- Radiotherapy should follow a wide local excision of a carcinoma of the breast in every case

Adjuvant systemic therapy

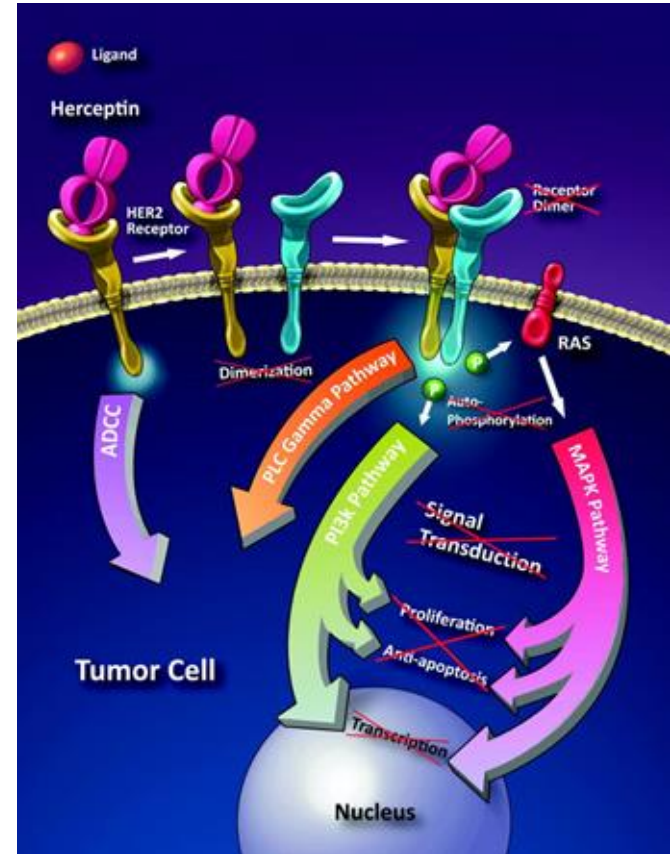
1. Chemotherapy

- Primary chemotherapy (Neoadjuvant)
 - The aim is to shrink large tumour to enable breast-conserving surgery to be performed rather than mastectomy
- Adjunctive therapy
 - To prolongs survival, particularly in patients with estrogen receptor-negative tumours
 - Combination of drugs are always used, for example cyclophosphamide, methotrexate and 5-fluorouracil (CMF) or regimens including anthracycline
 - Given in monthly cycles, usually for 6 months
 - Effective in pre-menopausal women

Adjuvant systemic therapy

2. Hormonal Therapy

- Targets the cancer specific genes, proteins, or the tissue environment that contributes to cancer growth and survival.
- HER2-targeted therapy
 - Eg : Trastuzumab (Herceptin®)
 - Over-expression of HER-2 indicates poorer prognosis.
 - Herceptin sticks to the HER2 protein, and prevents the epidermal growth factor from entering cancer cells
 - Used in HER-2 positive tumours, early or late stage
 - Adverse effects:
 - Cardiotoxicity : Cardiomyopathy & congestive cardiac failure
 - Pulmonary toxicity



Adjuvant systemic therapy

2. Hormonal Therapy

- **Selective Estrogen Receptor Modulator (SERM)**

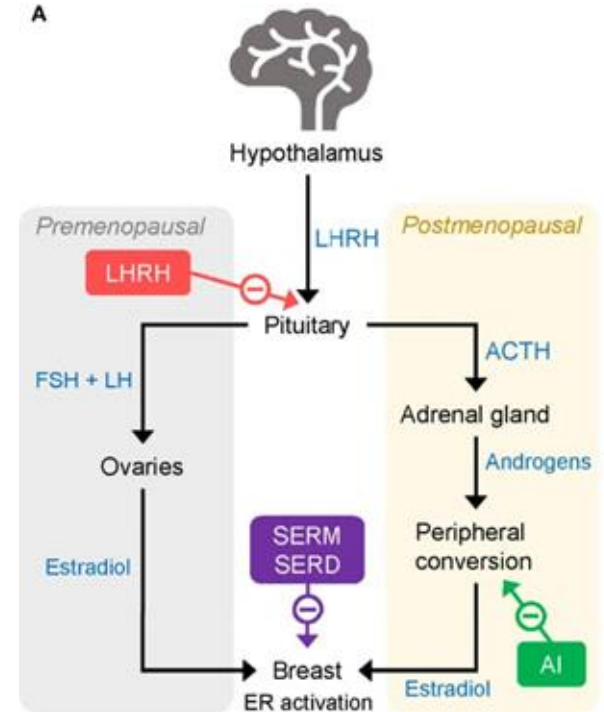
- Eg: Tamoxifen (Nolvadex®)
 - Blocks estrogen receptors on breast cancer cells
 - While tamoxifen acts like an anti-estrogen in breast cells, it acts like an estrogen in other tissues, like the uterus and the bones.
 - Can be given both to premenopausal and postmenopausal

- **Aromatase inhibitor (AI)**

- Eg: Letrozole(Femara), Exemestane(Aromasin), Anastrozole
 - Given to post-menopausal women as the main source of oestrogen is from the peripheral conversion of androgens by the aromatase enzyme
 - Inhibition of this enzyme will further reduction in oestrogen level which may be of benefit in patients with oestrogen receptor positive breast cancer

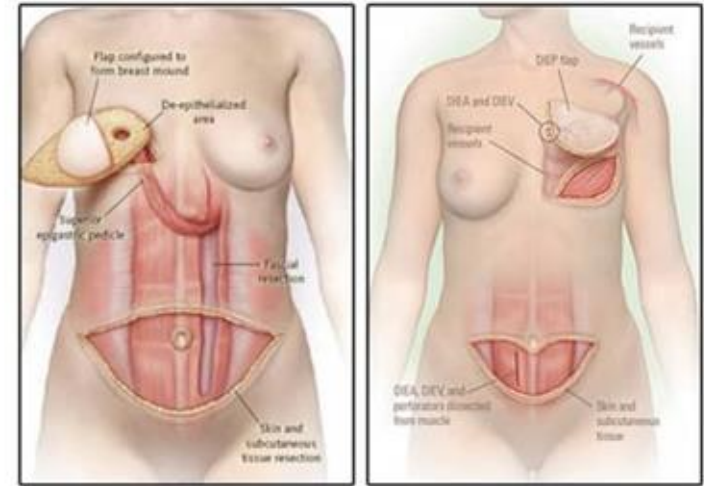
- **Luteinizing hormone-releasing hormone (LHRH) agonists**

- Eg: Goserelin
 - Induce reversible ovarian suppression thus have same beneficial effects as surgical or radiation-induced ovarian ablation in premenopausal receptor positive women and the oral AIs for postmenopausal women



Breast Reconstructive Surgery

- Reconstruction is usually performed some time after surgery when adjunctive radiotherapy or chemotherapy has been completed
- Can be carried out synchronously with mastectomy
- Breast implants - usually made of silicone - are widely used for augmentation of the normal breast for cosmetic purposes
- Reconstruction can be achieved by the use of autologous tissue transferred either from an adjacent area on a vascular pedicle or moved as a free transfer requiring micro-anastomosis of its blood supply
 - Latissimus dorsi flap
 - Transverse rectus abdominal muscle (TRAM) flap
 - Deep inferior epigastric perforator (DIEP) flap

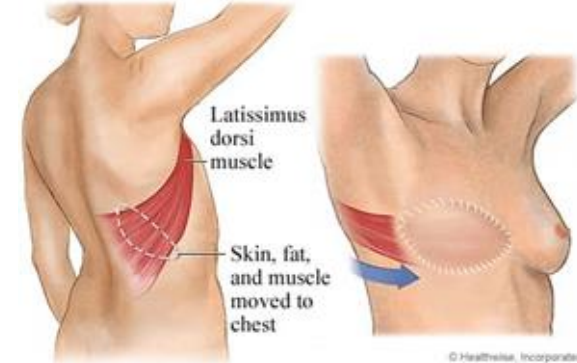


TRAM Flap

Lower abdominal skin, fat and one of the rectus muscle are transferred to the mastectomy site and contoured appropriately to reconstruct the breast.

DIEP Flap

The DIEP flap also uses the skin and fat from the lower portion of the abdomen, but spares the rectus muscle.



Follow-up

- Patients with breast cancer used to be followed for life to detect recurrence and dissemination.
 - First 2 years, regular follow up every 3-4 months
 - Subsequent 3 - 5 years , every 6-8 months
 - Annually thereafter.
- The interval of visits should be adapted to the risk of relapse and patients' needs. The recommended surveillance are:
 - annual ipsilateral (after BCS) and/or a contralateral mammography (after mastectomy), with US and breast MRI when needed
 - regular bone density evaluation for patients on AIs or undergoing ovarian function suppression
 - encouragement towards adopting a healthy lifestyle, including diet modification and exercise



REFERENCES

1. Talley and O'Connor's Clinical Examination 8th Edition
2. Clinical Anatomy, Keith L. Moore, Arthur F. Dalley, 6th Edition
3. CPG Management of Breast Cancer 2019 (Third Edition)